



## **Evaluation of *Vernonia amygdalina* Leaves for Gastroprotective Activity on Experimental Models of Gastric Ulcer in Rats**

**N. C. Azubuiké<sup>a\*</sup>, O. S. Onwukwe<sup>a</sup>, M. C. Ugwuodo<sup>b</sup> and M. Toni-Duruaku<sup>a</sup>**

<sup>a</sup> Department of Medical Laboratory Sciences, Faculty of Health Sciences and Technology, College of Medicine, University of Nigeria, Enugu Campus, Nigeria.

<sup>b</sup> Department of Anatomic Pathology and Forensic Science, College of Medicine, Enugu State University of Science and Technology, Nigeria.

### **Authors' contributions**

This work was carried out in collaboration among all authors. Author NCA conceptualized the study, designed the protocol, performed the investigations in the study, critically reviewed the literature, performed the statistical analysis, proof-read the first manuscript draft and wrote the final manuscript. Author OSO managed the literature searches and performed some investigations in the study. Author MCU also reviewed the literature and facilitated the animal experimentation. Author MTD collected data, managed the animal experimentation and wrote the first draft of the manuscript. All authors read and approved the final manuscript.

### **Article Information**

DOI: 10.9734/JOCAMR/2022/v19i2386

### **Open Peer Review History:**

This journal follows the Advanced Open Peer Review policy. Identity of the Reviewers, Editor(s) and additional Reviewers, peer review comments, different versions of the manuscript, comments of the editors, etc are available here: <https://www.sdiarticle5.com/review-history/91865>

**Original Research Article**

**Received 05 July 2022**  
**Accepted 09 September 2022**  
**Published 05 October 2022**

## **ABSTRACT**

**Background:** *Vernonia amygdalina* del. (*Arecaceae*) leaf, popularly known as 'Bitter leaf' is widely used as a leafy vegetable in soups and in folkloric medicine against many ailments including stomach discomfort.

**Aim:** The current study aimed to assess the gastroprotective effect of the crude aqueous extract of *V. amygdalina* leaves (AEVAL) on Hydrochloric acid (HCl)/Ethanol gastric ulcer models.

**Study Design:** An animal experimental study which was conducted for 14 days.

**Place and Duration of Study:** Department of Medical Laboratory Sciences, and Animal House, College of Medicine, University of Nigeria, Enugu Campus, between May 2013 and August 2014.

**Methodology:** Preliminary acute toxicity testing was performed. Twenty (25) rats were divided into five groups (n=5). Groups I and II were normal and ulcer control groups respectively. Groups III, IV

\*Corresponding author: E-mail: [nkiruka.azubike@unn.edu.ng](mailto:nkiruka.azubike@unn.edu.ng);

and V were pretreated with cimetidine (100 mg/kg), 250 mg/kg AEVAL and 500 mg/kg AEVAL respectively. Cimetidine and AEVAL were administered intraperitoneally and orally, respectively, once daily for 7 days. After drug treatments on Day 7, gastric ulcers were induced using HCl/ethanol solution (1ml/rat) prior to sacrifice. Ulcer indices and percentage ulcer inhibition were determined. The stomach tissues were excised, histologically processed and evaluated for histopathological alteration under light microscopy.

**Results:** Acute toxicity testing revealed that AEVAL at a dose of 5000 mg/kg body weight did not cause any mortality. Macroscopical evaluation of the gastric mucosa revealed severe lesions following induction with HCl/ethanol. However, profound protective effects were observed with cimetidine and AEVAL (250 and 500 mg/kg) pretreatments with ulcer inhibition of 79%, 58% and 76% respectively. Histopathological findings were consistent with the macroscopical features observed.

**Conclusion:** Data from this study suggest that oral treatment with *V. amygdalina* leaves extract exhibited gastroprotective activities against the injurious effects of acidified ethanol on the gastric mucosa of albino rats.

**Keywords:** *Vernonia amygdalina*; acidified ethanol; gastric ulcers; ulcer index; histopathology.

## 1. INTRODUCTION

*Vernonia amygdalina* del., a shrub plant (family: Asteraceae), is popular in most of West Africa and called 'Bitter leaves' due to its bitter stem and leaves. In Africa, especially Nigeria, the leaves are widely employed for medicinal purposes in folkloric medicine and also as a vegetable in soups. All parts of the plant, the roots, stem and leaves, are believed to be pharmacologically useful. There are folkloric claims that the extract from the plant can be used to relieve hiccups, stomach discomfort, fever, and also treat kidney problems [1]. Scientific evidence on its antioxidant, antidiabetic, nociceptive, antipyretic, anticancer, antihelmintic, anti-inflammatory, antimalarial and antimicrobial activities have been documented [2-10]. The bioactive compounds isolated from *V. amygdalina* include flavonoids, tannins, saponins, alkaloids, phenolics, steroidal glycosides, triterpenoids and terpenes [11].

Peptic ulcer is one of the commonest diseases of the gastro-intestinal mucosal surfaces with the major causative factor being the microorganism, *Helicobacter pylori*. Other risk factors that have increased the incidence of peptic ulcer include continuous exposure to stress, smoking, use of non-steroidal anti-inflammatory drugs, excessive alcohol intake and nutritional deficiencies [12-14]. In Nigeria, as in many other developing countries, peptic ulcer is one of the leading causes of mortality and morbidity [15]. The conventional drugs for its treatment are directed at the stimulation of mucosal defenses, reduction of gastric acid secretions, or by alleviation and/or treatment of the aggressive factors [16]. The

major drawbacks associated with the use of these orthodox medicines are their side effects and limited efficacy against gastric diseases [17]. These have warranted the continuous search for new drugs from medicinal plants with gastroprotective and anti-ulcer potential. The cheaper cost, availability and wider safety margin of natural products have made them a preferred source of remedy when the health is challenged. Since there is a need to exploit natural products as potential therapeutic agents, the present study sought to investigate the gastroprotective effects of *V. amygdalina* aqueous leaf extract against acidified ethanol-induced gastric ulcers in rats.

## 2. MATERIALS AND METHODS

### 2.1 Collection and Preparation of Plant Material

Fresh leaves of *V. amygdalina* leaves were purchased from the 'Akwata' section of Ogbete Main Market, Enugu, Enugu State, Nigeria. For specimen authentication, a sample of the plant material was sent to an expert at the herbarium section of the Department of Plant Science and Biotechnology, University of Nigeria, Nsukka. The leaves were rinsed in distilled water and dried under a shade for two weeks. The dried leaves were ground finely using a gasoline-powered grinding machine. 200 g of the powder was homogenized in 600 ml of distilled water and shaken intermittently for 10 hours and thereafter sieved twice with a muslin cloth. The homogenate was eventually stored in an air-tight container, labeled as 'AEVAL' (aqueous extract of *V. amygdalina* leaves) and refrigerated at 2-8°C until needed.

## 2.2 Acute Toxicity Studies

The variation method as described by Lorke [18] with slight modification was used for the acute toxicity testing of the extract in rats. This was conducted to determine the oral lethal median dose [LD<sub>50</sub>]. This procedure involved a single dose administration of three (3) doses of the extract (1000 mg/kg, 2000 mg/kg and 5000 mg/kg) orally to three (3) respective groups of rats (n=3) after an overnight fasting. The animals were kept under normal laboratory conditions and allowed free access to water only. The rats were observed for 24 hours for clinical signs of toxicity and mortality.

## 2.3 Laboratory Animals

Twenty-five (25) albino Wistar rats (weighing between 150-180 g) of approximately 3 months old were used. The animals were procured from the Animal House of the Department of Physiology, College of Medicine, University of Nigeria, Enugu Campus (UNEC), Nigeria. The animals were housed at the Animal Housing Unit (Annex) of the College of Medicine, UNEC. They were kept in clean wire-mesh cages with openings underneath, wide enough to allow passage of fecal droppings. The animal facility was under standard environmental conditions of humidity, light (12 h light/dark cycle) and temperature (25±2°C). The animals were fed with clean water and commercially available Standard rat pellets (Guinea feed® Nigeria Plc) *ad libitum*. Prior to the commencement of the experiment, the rats were allowed to acclimatize for one week.

## 2.4 Experimental Design and Drug Treatment

The animals were randomly divided into five (5) groups (I – V) (n = 5) namely: normal control (Group I), Ulcer model (Group II), Cimetidine (Group III), Low dose AEVAL (Group IV), and High dose AEVAL (Group V). Rats in normal and ulcer control groups received no drug treatment. Those in groups III, IV and V received 100 mg/kg body weight (b. wt.) of Cimetidine (intraperitoneally), 250 mg/kg b.wt. of AEVAL and 500 mg/kg b.wt. of AEVAL, respectively, once daily for 7 days. All AEVAL treatments were performed by oral gavage via an orogastric tube.

## 2.5 Acute Gastric Ulcer Induction

The experimental acute gastric ulcer induction was achieved using oral administration of the

necrotizing agent (HCl/Ethanol). The rats were fasted for 24 hours after the last drug treatments on Day 6 but they were given free access to clean water. On Day 7, drug treatments were given and after 30 mins, each rat in groups II to V was treated with 1ml of HCl/Ethanol (80% ethanol in 0.1N HCl) orally with an oral cannula. Animal sacrifice was performed one hour later under mild chloroform anesthesia. The stomach tissue of each rat was excised and a careful incision was made along the line of greater curvature in order to expose the inner gastric surface. The gastric contents were rinsed off with physiological saline prior to necropsy.

## 2.6 Macroscopical Examination

The gastric surface of each stomach tissue was examined macroscopically for the presence and severity of ulcerative lesions using a hand magnifying lens (x10 amplification) [19,20]. An arbitrary scale of 0 – 4 was used to score the severity of the gastric lesions as described previously [21] but with slight modification. Scores were given as follows: 0 for no lesion, 0.5 for hyperemia, 1 for one or two lesions, 2 for multiple lesions with variable severity, 3 for very severe lesions, and 4 for active hyperemia with full mucosal lesions. The mean of ulcer scores was recorded as the ulcer index (UI). The percentage protection (PP) for each rat was thereafter determined as shown below:

$$\frac{\text{UI (control)} - \text{UI (treated)}}{\text{UI (control)}} \times 100$$

Photomacrography was performed to capture the macroscopical images of the gastric mucosal tissues.

## 2.7 Histopathological Studies

The stomach tissues, after necropsy, were immediately placed in tissue cassettes and labeled accordingly. Prior to routine histological processing using the Automatic Tissue Processor, all the tissues were fixed in 10% formal saline for at least 48 hours. Paraffin wax embedding and sectioning at 3 – 5 µm thickness with Rotary Microtome (Heitz 150, Cambridge model) were performed. General tissue structure for each section under light microscopical examination was demonstrated by employing the Hematoxylin and Eosin routine staining technique [22]. Microscopical examination of the tissue sections was done using an Olympus Binocular

microscope with in-built lighting system. Light photomicrographs (at x100 and x400 total magnification) were captured afterwards using an eyepiece microscope digital camera. (AmScope - MU300 series model).

## 2.8 Statistical Analysis

Data obtained from this study were expressed, where appropriate, as mean  $\pm$  S.E.M. of five rats/group. Statistical analysis was conducted using version 23.0 of Statistical Package for Social Sciences [SPSS] software (SPSS, Chicago, IL). Data were subjected to one-way analysis of variance (ANOVA), followed by Tukey-highest significant difference (HSD) post-hoc test to determine the differences among the groups. The level of significance was considered at  $p$  value of  $<0.05$ .

## 3. RESULTS AND DISCUSSION

The preliminary acute toxicity testing conducted showed that the extract at the highest dose of 5000 mg/kg body weight, did not produce severe signs or symptoms of toxicity and even mortality. Thus, from this finding, it can be inferred that the medial lethal dose ( $LD_{50}$ ) of the aqueous extract of *V. amygdalina* leaves is greater than 5000 mg/kg b.w. It is well established that substances with such an  $LD_{50}$  value are considered relatively non-toxic. Studies from previous researchers have also documented similar reports and concluded that *V. amygdalina* aqueous leaf extract is unlikely to be hazardous having exhibited no signs of toxicity or mortality up to a dose of 5000 mg/kg [23-25], whereas Ojiako and Nwanjo [26] reported that the extract may be toxic when consumed in very large quantities.

In the animal experimentation in the present study, the effect of treatment with *V. amygdalina* leaves extract on HCl/ethanol-induced gastric ulcers in rats was evaluated. Hydrochloric acid (HCl) in combination with ethanol is well-known to produce necrotizing lesions on the gastric mucosa when administered orally. The lesions produced by HCl/ethanol administration have been reported to be more severe than those produced by treatment with absolute ethanol only as it further accelerates ulcerogenesis and increases tissue injury [27,28]. HCl/ethanol increases peptic acid secretion, reduces the protective layer of mucus, causes intracellular oxidative stress, reduces the levels of proteins in the tissue resulting in tissue injury [29,30].

Treatment of rats with HCl/ethanol only in ulcer model group (negative control) in the present study, showed to a great extent, more severe mucosal lesions when compared to the other treatment groups, thus confirming the necrotizing effects of HCl/ethanol treatment on stomach tissues.

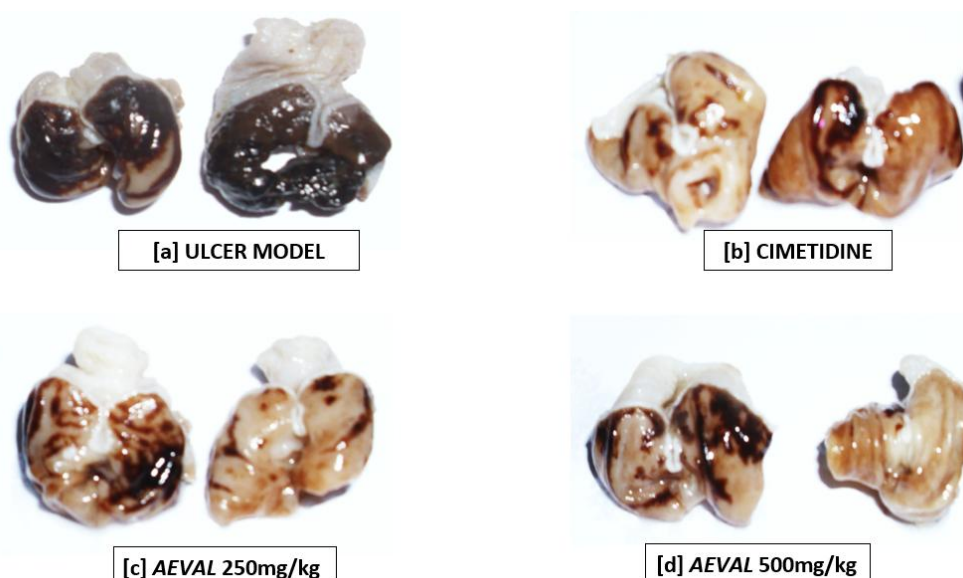
Macroscopical examination (necropsy) of the stomach tissues from the ulcer model group revealed intense gastric mucosal lesions with evidence of ulcers and hemorrhagic streaks (Fig. 1a). Previous studies have reported similar effects after an acute gastric ulcer induction with HCl/ethanol oral administration [31,32]. Treatment with the reference drug, cimetidine, and the two doses (250 and 500 mg/kg b.wt) of the extracts produced markedly reduced lesions (Figs. 1b, 1c and 1d respectively) when compared to the ulcer model. The necropsy findings are better portrayed by the ulcer index (UI) and percentage protection (PP) determination as shown in Table 1. The highest UI of  $3.80 \pm 0.22$  was obtained for the ulcer model group and the least from cimetidine-treated group with a value of  $0.80 \pm 0.12$  and best PP of 79%. The higher dose of AEVAL (500 mg/kg b.wt.) showed a better gastroprotective ability than the lower dose (250 mg/kg b.wt.) with UI values of  $1.60 \pm 0.24$  and  $0.90 \pm 0.10$  respectively with corresponding PP values of 58% and 76% respectively.

The micro-anatomical findings corroborate with the necropsy reports in the present study. This further revealed that the histoarchitecture of the stomach sections from the ulcer model group was severely disorganized. Marked ulceration and degeneration of the gastric glands in the mucosa were observed (Fig. 2b). Clear differences can be observed in comparison with the stomach sections of normal control rats (given no treatment) which showed intact tissue (Fig. 2a). The stomach section from cimetidine-treated group (Fig. 2c) showed evidence of marked cytoprotection from the injurious impact exerted by the necrotizing agent. This proves the potency of this drug hence its use as a standard anti-ulcer drug. Apart from possessing cytoprotective properties, cimetidine is an H<sub>2</sub>-receptor antagonist and hence acts by blocking the effect of histamine thereby inhibiting gastric acid secretion [33].

A similar cytoprotective ability was observed by treatments with the two doses of the extract (Figs. 2d and 2e), although a better preservation

of the tissue cytoarchitecture was observed with the higher dose (Fig. 2e), corroborating with the necropsy findings. This finding suggests that oral administration of *V. amygdalina* aqueous leaves extract provides a protective role for the mucosal lining of the stomach tissues against lesions induced by HCl/ethanol-induced ulcers. This was evidenced by the better organization of the stomach tissues, though with minor lesions, following *V. amygdalina* treatment when compared with the ulcer model group. The effect produced by the extract may be a mimic of the mechanism of action of cimetidine thereby modulating gastric mucosal cells against excessive acid secretion. Overall, the observed effects of *V. amygdalina* leaves extract could be

attributed to one or more of its phytochemical constituents especially polyphenolic compounds like flavonoids. Owolabi et al. [34] documented that *V. amygdalina* leaves are rich in antioxidants majorly due to its flavonoid content. Since the action of acidified ethanol on the gastric tissues is mediated via the release of free radical species, it can then be inferred that the extract may have acted significantly in the strengthening of the gastric mucosal walls and consequently protecting the tissues from oxidative damage. Previous researchers have also associated the gastroprotective potentials of plant materials to their polyphenolic compounds (such as flavonoids and tannins) and other bioactive principles [16,35,36].



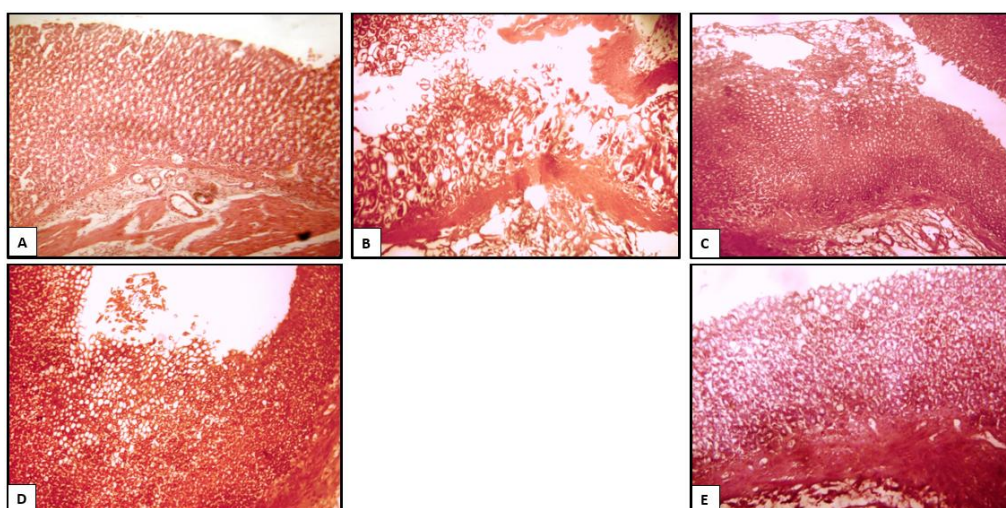
**Fig. 1. Gastroprotective effects of *V. amygdalina* leaves extract on acidified ethanol-induced ulcers in rats**

*Illustrative photomicrographs of Stomach tissues opened from the line of greater curvature to expose the inner gastric surface. Ulcer model group [a]: Extensive obvious hemorrhagic necrosis is observed in the gastric mucosa of rats treated with HCl/ethanol only. Cimetidine group [b]: Pretreatment with Cimetidine 100mg/kg i.p. significantly reduced the injuries from HCl/ethanol as seen in ulcer control model. AEVAL 250 mg/kg [c] and AEVAL 500 mg/kg [d] groups: Pretreatment with both doses of *V. amygdalina* extract also significantly prevented gastric mucosal injuries from HCl/ethanol*

**Table 1. Effects of *Vernonia amygdalina* leaves extract on necrotizing agent-induced ulceration**

Treatments	n	Dose	UI (mean $\pm$ SEM)	PP (%)
Ulcer model	5	10 ml/kg	3.80 $\pm$ 0.20	
Cimetidine	5	100 mg/kg	0.80 $\pm$ 0.12*	79
Low Dose AEVAL	5	250 mg/kg	1.60 $\pm$ 0.24*	58
High Dose AEVAL	5	500 mg/kg	0.90 $\pm$ 0.10*	76
<b>F-ratio</b>			62.373	
<b>Sig.</b>			0.000	

*Data expressed as mean  $\pm$  SEM. \* $p < 0.05$  statistical significant when compared to the control group. AEVAL = Aqueous extract of *Vernonia amygdalina* leaves; UI: Ulcer Index; PP: Percentage Protection*



**Fig. 2. Light photomicrographs of stomach sections from control and treatment groups (A - E)**  
**[Stain: H&E; Mag.: x100]**

[A] Normal control: Intact histoarchitecture of the gastric mucosa. [B] Ulcer model: Section shows evidence of mucosal disorganization, gastric gland degeneration and erosion. [C] Cimetidine 100 mg/kg: Showing significantly preserved tissue structure with mild damage of superficial mucosal cells. [D] AEVAL 250 mg/kg: showing moderately preserved tissue structure. [E] AEVAL 500 mg/kg: General features appear intact and markedly preserved tissue but with mildly eroded superficial cells

#### 4. CONCLUSION

Findings from the present study confirms that oral administration of hydrochloric acid in combination with ethanol exerts severe gastric mucosal lesions. However, upon administration of the aqueous leaves extract of *Vernonia amygdalina*, significant gastroprotective effects were observed. All the evidence from the macroscopical and microscopical findings in the present study revealed that *Vernonia amygdalina* can be further explored for its cytoprotective abilities in maintaining the structural integrity of the stomach tissues against injurious impact from gastro-toxic agents. Bioactive principle(s) isolation to determine the compound(s) responsible for the observed effects and their possible mode of action(s) may be conducted in future studies.

#### CONSENT

It is not applicable.

#### ETHICAL APPROVAL

All authors hereby declare that "Principles of laboratory animal care" (NIH publication No. 85-23, revised 1985) were followed, as well as specific national laws where applicable. All experiments have been examined and approved by the appropriate Institutional ethics committee. Animal housing and handling protocols were

performed in strict accordance to guidelines describing the use of rats for research.

#### ACKNOWLEDGEMENTS

The authors wish to acknowledge the staff of the Animal Housing Unit of the College of Medicine for their kind usual support and assistance.

#### COMPETING INTERESTS

Authors have declared that no competing interests exist.

#### REFERENCES

1. Adetunji CO, Olaniyi OO, Ogunkunle ATJ. Bacterial activity of crude extracts of *Vernonia amygdalina* on clinical isolates. *Journal of Microbiology and Antimicrobials*. 2013;5(6):60-64.
2. Nwanjo HU. Efficacy of aqueous leaf extract of *Vernonia amygdalina* on plasma lipoprotein and oxidative status in diabetic rat models. *Nigerian Journal of Physiological Sciences: Official Publication of the Physiological Society of Nigeria*. 2005;20(1-2):39-42.
3. Letchuman GR, Nazaimoon WMW, Mohamad WBW, Chandran LR, Tee GH, Jamayah H, Faudzi YA. Prevalence of diabetes in the Malaysian national health

- morbidity survey III 2006. Medical Journal of Malaysia. 2010;65(3):173-9.
4. Georgewill OA, Georgewill UO. Evaluation of the anti-inflammatory activity of extract of *Vernonia amygdalina*. Asian Pacific Journal of Tropical Medicine. 2010;150-51.
  5. Wong FC, Woo CC, Hsu A, Tan BKH. The anti-cancer activities of *Vernonia amygdalina* extract in human breast cancer cell lines are mediated through caspase-dependent and p53-independent pathways. Plos One. 2013;8(10):1-15.
  6. Ghamba P, Balla H, Goje L, Halidu A, Dauda M. *In vitro* antimicrobial activities of *Vernonia amygdalina* on selected clinical isolates. International Journal of Current Microbiology and Applied Sciences. 2014;3(4):1103-13.
  7. Egharevba C, Osayemwenre E, Imieje V, Ahomafor J, Akunyuli C, Udu-Cosi AA, Theophilus, O, James O, Ali I, Falodun A. Significance of bitter leaf (*Vernonia amygdalina*) in tropical diseases and beyond: A review. Malaria Chemotherapy Control and Elimination. 2014;3(1):1-10.
  8. Adedapo AA, Aremu OJ, Oyagbemi AA. Anti-oxidant, anti-inflammatory and antinociceptive properties of the acetone leaf extract of *Vernonia amygdalina* in some laboratory animals. Advanced pharmaceutical bulletin. 2014;4(2):591.
  9. Adiukwu PC, Kayanja FIB, Nambatya GK, Rugera S, Ezeonwumelu JOC, Tanayen JK, Murokore BJ, Twikirize O, Twinomujuni S, Byamugisha D, Imanirampa L. Antipyretic and antinociceptive properties of the aqueous extract and saponin from an edible vegetable: *Vernonia amygdalina* leaf. African Journal of Food, Agriculture, Nutrition and Development. 2013;13(2): 1019-28.
  10. Alawa CBI, Adamu AM, Gefu JO, Ajanusi OJ, Abdu PA, Chiezey NP, Alawa JN, Bowman DD. *In vitro* screening of two nigerian medicinal plants (*Vernonia amygdalina* and *Annona senegalensis*) for anthelmintic activity. Veterinary Parasitology. 2003;113(1):73-81.
  11. Alara OR, Abdurahman NH, Mudalip SKA, Olalere OA. Phytochemical and pharmacological properties of *Vernonia amygdalina*: A review. Journal of Chemical Engineering and Industrial Biotechnology. 2017;2(1):80-96.
  12. Chaturvedi A, Kumar MM, Bhawani G, Chaturvedi H, Kumar M, Goel KR. Effect of ethanolic extract of *Eugenia jambolana* seeds on gastric ulceration and secretion in rats. Indian J Physiol Pharmacol. 2007;51(2):131-40.
  13. Laine L, Takeuchi K, Tarnawski A. Gastric mucosal defense and cytoprotection: Bench to bedside. Gastroenterology. 2008;135(1):41-60.
  14. Scheiman JM. NSAID-induced gastrointestinal injury: A focused update for clinicians. Journal of Clinical Gastroenterology. 2016;50(1):5-10.
  15. Agbakwuru EA, Fatusi AO, Ndububa DA, Alatise OI, Arigbabu OA, Akinola DO. Pattern and validity of clinical diagnosis of upper gastrointestinal diseases in south-west Nigeria. African Health Sciences. 2006;6(2):98-103.
  16. Borrelli F, Izzo AA. The plant kingdom as a source of anti-ulcer remedies. Phytotherapy research: An international journal devoted to pharmacological and toxicological evaluation of natural product derivatives. 2000;14(8):581-91.
  17. Luiz-Ferreira A, de Almeida ACA, Cola M, Barbastefano V, De Almeida ABA, Batista LM, Farias-Silva E, Pellizzon CH, Hiruma-Lima CA, Santos LC, Vilegas W. Mechanisms of the gastric antiulcerogenic activity of *Anacardium humile* St. hil on ethanol-induced acute gastric mucosal injury in rats. Molecules. 2010;15(10): 7153-66.
  18. Lorke D. A new approach to practical acute toxicity testing. Archives of Toxicology. 1983;54(4):275-87.
  19. Bharti S, Wahane VD, Kumar VL. Protective effect of *Calotropis procera* latex extracts on experimentally induced gastric ulcers in rat. Journal of Ethnopharmacology. 2010;127(2):440-4.
  20. Souza RH, Cardoso MS, Menezes CT, Silva JP, De Sousa DP, Batista JS. Gastroprotective activity of  $\alpha$ -terpineol in two experimental models of gastric ulcer in rats. DARU: Journal of Faculty of Pharmacy, Tehran University of Medical Sciences. 2011;19(4):277.
  21. MacAllister CG, Andrews FM, Deegan E, Ruoff W, Olovson SG. A scoring system for gastric ulcers in the horse. Equine Veterinary Journal. 1997;29(6):430-3.
  22. Baker FJ, Silverton RE, Pallister CJ. Staining procedures. Introduction to Medical Laboratory Technology; 2001.
  23. Adiukwu PC, Amon A, Nambatya G, Adzu B, Imanirampa L, Twinomujuni S, Twikirize

- O, Amany M, Ezeonwumelu JO, Oloro J, Okoruwa GA. Acute toxicity, antipyretic and antinociceptive study of the crude saponin from an edible vegetable: *Vernonia amygdalina* leaf. International Journal of Biological and Chemical Sciences. 2012;6(3):1019-1028.
24. Zakaria Y, Azlan NZ, Fakhruddin N, Hassan N, Muhammad H. Phytochemicals and acute oral toxicity studies of the aqueous extract of *Vernonia amygdalina* from state of Malaysia. Journal of Medicinal Plants Studies. 2016;4(3):1-5.
  25. Bihonegn T, Giday M, Yimer G, Animut A, Sisay M. Antimalarial activity of hydromethanolic extract and its solvent fractions of *Vernonia amygdalina* leaves in mice infected with *Plasmodium berghei*. SAGE Open Medicine. 2019;7: 2050312119849766.
  26. Ojiako OA, Nwanjo HU. Is *Vernonia amygdalina* hepatotoxic or hepatoprotective? Response from biochemical and toxicity studies in rats. African Journal of Biotechnology. 2006;5 (18):1648-51.
  27. Singh S, Khajuria A, Taneja SC, Khajuria RK, Singh J, Johri RK, Qazi GN. The gastric ulcer protective effect of boswellic acids, a leukotriene inhibitor from *Boswellia serrata*, in rats. Phytomedicine. 2008;15(6-7):408-15.
  28. Fernandes HB, Silva FV, Passos FF, Bezerra RD, Chaves MH, Oliveira FA, Meneses Oliveira RC. Gastroprotective effect of the ethanolic extract of *Parkia platycephala* Benth leaves against acute gastric lesion models in rodents. Biological Research. 2010;43(4):451-7.
  29. Anandan R, Nair PV, Mathew S. Anti-ulcerogenic effect of chitin and chitosan on mucosal antioxidant defence system in HCl-ethanol-induced ulcer in rats. Journal of Pharmacy and Pharmacology. 2004;56(2):265-9.
  30. Batista LM, De Almeida AB, De Pietro Magri L, Toma W, Calvo TR, Vilegas W, Brito AR. Gastric antiulcer activity of *Syngonanthus arthrotrichus* Silveira. Biological and Pharmaceutical Bulletin. 2004;27(3):328-32.
  31. Alrashdi AS, Salama SM, Alkiyumi SS, Abdulla MA, Hadi AH, Abdelwahab SI, Taha MM, Hussiani J, Asykin N. Mechanisms of gastroprotective effects of ethanolic leaf extract of *Jasminum sambac* against HCl/ethanol-induced gastric mucosal injury in rats. Evidence-Based Complementary and Alternative Medicine; 2012.
  32. Kim YS, Lee JH, Song J, Kim H. Gastroprotective effects of *Inulae flos* on HCl/Ethanol-Induced gastric ulcers in rats. Molecules. 2020;25(23):5623.
  33. Fosca A, Sava A, Ababei A, Apotrosoaei. Drug interactions in gastrointestinal disorders therapy. Romanian Journal of Pharmaceutical Practice. 2021;14: 25-29.
  34. Owolabi MA, Jaja SI, Oyekanmi OO, Olatunji OJ. Evaluation of the antioxidant activity and lipid peroxidation of the leaves of *Vernonia amygdalina*. Journal of Complementary and Integrative Medicine. 2008;5(1).
  35. Sannomiya M, Fonseca VB, Da Silva MA, Rocha LR, Dos Santos LC, Hiruma-Lima CA, Brito AS, Vilegas W. Flavonoids and antiulcerogenic activity from *Byrsonima crassa* leaves extracts. Journal of Ethnopharmacology. 2005;97 (1):1-6.
  36. Mota KSDL, Dias GEN, Pinto MEF, Luiz-Ferreira A, Brito ARMS, Hiruma-Lima C, Barbosa-Filho J, Batista LM. Flavonoids with gastroprotective activity. Molecules. 2009;14(3):979-1012

© 2022 Azubuikwe et al.; This is an Open Access article distributed under the terms of the Creative Commons Attribution License (<http://creativecommons.org/licenses/by/4.0>), which permits unrestricted use, distribution, and reproduction in any medium, provided the original work is properly cited.

Peer-review history:  
The peer review history for this paper can be accessed here:  
<https://www.sdiarticle5.com/review-history/91865>