

## **Fibrous Dysplasia: A Retrospective Review of Histologically Diagnosed Cases in a Tertiary Health Care Centre in Nigeria**

**Philip O. Akpa<sup>1,2\*</sup>, Barka V. Kwaghe<sup>1</sup>, Christiana Nwanneka Ibeanu<sup>1</sup> and Pricilla Ometere Onota<sup>1</sup>**

<sup>1</sup>Department of Histopathology, Jos University Teaching Hospital, P. M. B 2076, Jos Plateau State, Nigeria.

<sup>2</sup>Department of Histopathology, University of Jos, P. M. B 2084, Jos Plateau State, Nigeria.

### **Authors' contributions**

*This study was carried out by all the authors working in collaboration. Author POA conceptualized the study, carried out literature search and wrote the initial draft. Authors BVK, CNI and POO gathered the data and analyzed it. Author POA edited the manuscript. All authors reviewed and approved the final manuscript.*

### **Article Information**

DOI: 10.9734/JCTI/2021/v11i330153

Editor(s):

(1) Dr. Pandiaraja. J, Shree Devi Hospital, India.

Reviewers:

(1) Maifata, Sadiq Muazu, Federal University of Lafia, Nigeria.

(2) Jamal Ahmad Saleem Alshorman, Huazhong University of Science and Technology, China.

(3) Bojinca Violeta Claudia, University of Medicine and Pharmacy "Carol Davila" Bucharest, Romania.

Complete Peer review History: <http://www.sdiarticle4.com/review-history/69355>

**Original Research Article**

**Received 23 March 2021**  
**Accepted 02 June 2021**  
**Published 05 June 2021**

### **ABSTRACT**

**Aims:** This study aims to document the age, sex and site distribution of fibrous dysplasia in our tertiary health care facility in order to compare our findings with published literature.

**Study Design:** This is a hospital-based retrospective and descriptive study extending from 1st January 2005 to 31st December 2019.

**Place and Duration of Study:** Department of Histopathology, Jos University Teaching Hospital, Jos, Plateau State in North-Central Nigeria between 1st January 2005 to 31st December 2019.

**Materials and Methods:** Materials consisted of Archival slides, paraffin wax tissue blocks, surgical pathology register and case files of all cases of fibrous dysplasia diagnosed histologically during the period of review. The age, sex and site affected by the tumour were documented for each case using both electronic and hard copy records. The histology slides were examined to confirm the

diagnosis. A total of 165 primary bone tumours (103 benign and 63 malignant) were recorded during the period of review, of which 28 were fibrous dysplasia.

**Results:** There were 28 cases of fibrous dysplasia which represented 17% of the primary bone tumours and 27% of the benign bone tumours. A half (50%) of the cases occurred in the second decade and 82.1% of cases were diagnosed in craniofacial bones. There was no sex bias in diagnosis.

**Conclusion:** Fibrous dysplasia is a relatively common bone tumour in our environment. The sex distribution, age at diagnosis, and bones affected is in keeping with findings by authors from other parts of the world.

*Keywords: Fibrous dysplasia; primary bone tumour; monostotic; craniofacial; Jos; Nigeria.*

## 1. INTRODUCTION

Fibrous dysplasia is a benign medullary fibro-osseous lesion in which normal bone is replaced by irregularly shaped immature bone and fibrous connective tissue [1-4]. This lesion can occur in the monostotic form with a solitary lesion affecting one bone or the polyostotic form with lesions affecting multiple bones [5-7]. The polyostotic form can occur in association McCune-Albright syndrome (polyostotic fibrous dysplasia occurring in association with café-au-lait skin macules and endocrine abnormalities) and Mazabraud's syndrome (polyostotic fibrous dysplasia in association with soft tissue myxomas) [1,5-8,].

The monostotic form of fibrous dysplasia accounts for between 70-80% of all cases of fibrous dysplasia and the polysostotic form represents 20-30% [2,8-9]. Fibrous dysplasia is grouped among bone tumours of undefined neoplastic nature which were formally called tumour-like lesions of bone. An activating mutation in the cell surface G protein receptor which occurs postzygotically results in hyperactivity of the affected cells giving rise to fibrous dysplasia lesions [5-7,9-11]. Fibrous dysplasia is considered a congenital non-hereditary disease [1,9].

As many as 75% of patients with fibrous dysplasia present within the first three decades of life, however presentation is earlier for patients with the polyostotic form in which a majority present in the first decade [11-12]. The monostotic form of fibrous dysplasia does not show a gender bias, while the polyostotic form shows a female predilection [2]. Fibrous dysplasia can affect any bone with, the craniofacial bones, femur and ribs among the common sites of diagnosis [5,11-13]. The polyostotic form has a high tendency of affecting the craniofacial bones and a tendency to involve

bones on only one side of the body in some patients [2].

The presenting signs/symptoms of fibrous dysplasia is dependent on the location and size of the lesion [1,5]. It can be asymptomatic and be detected during skeletal survey for an unrelated pathology [8,11]. Lesions of fibrous dysplasia usually appear as a replacement of the trabecular pattern of bone by a ground glass appearance on radiographs [11]. A definitive diagnosis usually requires a histopathological analysis due to the difficulty in differentiating it clinically and radiologically from some of its differential diagnosis especially in the craniofacial lesions [1]. Common differentials of fibrous dysplasia include Non-ossifying fibroma, aneurysmal bone cyst, adamantinoma, giant cell tumour, low grade osteosarcoma and Paget's disease of bone [1,2,11,12]. This study aims to analyze the age at diagnosis, sex, and site affected by fibrous dysplasia diagnosed in our health facility and to compare our findings to other published literature.

## 2. MATERIALS AND METHODS

This is a retrospective review of all cases of fibrous dysplasia diagnosed histologically at the Jos university Teaching Hospital (JUTH) department of Histopathology between 1st January 2005 to 31st December 2019. Materials utilized for this research consisted of Archival slides, paraffin wax tissue blocks (in cases of missing or poor quality slides), surgical pathology register and case files of all cases of fibrous dysplasia diagnosed during the period of review. Only cases of fibrous dysplasia diagnosed by histology were included in the study, while cases diagnosed radiologically were excluded. The patient sex, age at diagnosis and site affected by the tumour were documented for each case. All cases of primary bone tumour were reviewed for the purpose of this study in order to calculate the

relevant percentages for fibrous dysplasia. All cases were reviewed by the authors of this article. The data was analyzed utilizing Epi info 7 (version 3.5.4) and presented in tables.

### 3. RESULTS

A total of 165 primary bone tumours were documented in the period of review of which 103 were benign and 62 malignant. There were 28 cases of fibrous dysplasia (which accounted for 17% of primary bone tumours and 27% of benign

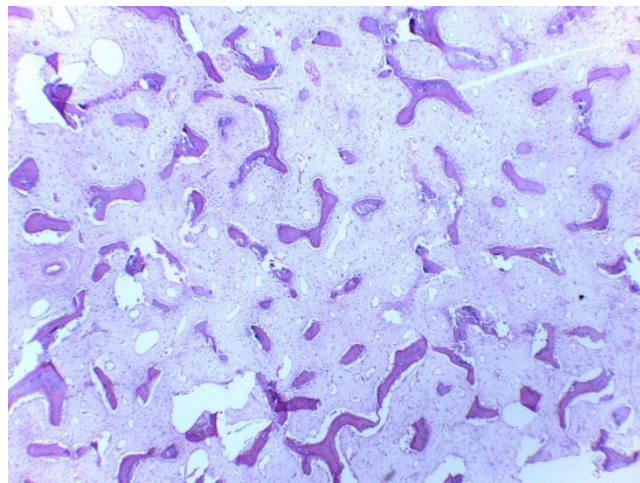
bone tumours). Fibrous dysplasia was equally as common as osteochondroma with both being the commonest benign bone tumours diagnosed in our study. Fibrous dysplasia occurred in equal frequency in males and females (14 males and 14 females). The peak age range of diagnosis is the second decade with a mean age of  $22.7 \pm 12$  years (Table 1). The commonest site of fibrous dysplasia diagnosis was in the craniofacial bones which accounted for 82.1% of cases (Table 2). There were no cases of polyostotic fibrous dysplasia in our study.

**Table 1. Table showing age distribution of fibrous dysplasia**

AGE RANGE	Frequency	Percentage
0-10	2	7.1
11-20	14	50.0
21-30	6	21.4
31-40	3	10.7
41-50	2	7.1
51-60	1	3.6
>60	-	-
Total	28	100

**Table 2. Table showing anatomical site distribution of fibrous dysplasia**

SITE OF TUMOUR	Frequency	Percentage
Craniofacial bones	23	82.1
<i>Maxilla---14</i>		
<i>Mandible---8</i>		
<i>Fronto-orbital bone---1</i>		
Tibia	2	7.1
Ulna	1	3.6
Hand bones (little finger)	1	3.6
Foot bones (hallux)	1	3.6
Total	28	100



**Fig. 1. Photomicrograph (Haematoxylin and eosin x100) of fibrous dysplasia showing irregular, curvilinear trabeculae of bone lacking osteoblastic rimming disposed in a loose fibrous stroma**

#### 4. DISCUSSION

Fibrous dysplasia accounts for between 0.8-2.5% of primary bone tumours and 5-7% of benign bone tumours, however the true incidence is difficult to determine because some affected individuals are asymptomatic [2,8,10,12,14]. Fibrous dysplasia accounted for 17% of primary bone tumours and 27% of benign bone tumours in our study which is significantly higher than the figures seen worldwide [4,5,7]. The documented percentage in studies from other geographical parts of Nigeria appear to also be high but vary significantly. In Lagos (South-western Nigeria), Enugu (South-eastern Nigeria) and Zaria (North-western Nigeria), the documented percentages of fibrous dysplasia amongst benign bone tumours were 6.6%, 23.4%, and 33.8% respectively [15-17]. The higher incidence in our environment may be coincidental, however a genetic or environmental factor needs to be investigated.

Fibrous dysplasia frequently presents in children and adolescents but the monostotic form may be asymptomatic and present well into adulthood [4]. An estimated 75% of all fibrous dysplasia present before the age of 30 years, (60% of the polyostotic forms present before the age of 10 years while the peak for the monostotic form occurs in the second decade) [2,8,11]. The peak age of diagnosis of fibrous dysplasia occurred in the second decade in our study (50% of cases occurred between 11-20 years) and 78.5% of cases occurred in patients 30 years and below. These findings correlate with most local and international published literature [2,8,17]. There was no sex bias in fibrous dysplasia diagnosis in our study with a male to female ratio of 1:1 (M:F=1:1) and is in keeping with the trend worldwide [2,4]. There were no cases of polyostotic fibrous dysplasia in our study.

Fibrous dysplasia can occur in any bone, common sites of diagnosis are the craniofacial bones, proximal femur and ribs [5,11]. The most common site of fibrous dysplasia diagnosis is in craniofacial bones, with the maxilla being involved more frequently than other craniofacial bones [2,3,11,14]. A majority of fibrous dysplasia cases in our study, 23 (82.1%) out of a total of 28 occurred in craniofacial bones, which correlates with the findings of authors in Nigeria and other parts of the world [4,16,17].

Fibrous dysplasia has a clear but rare potential for malignant transformation [1,5,8,11].

Osteosarcoma is the commonest secondary malignancy encountered, but chondrosarcoma and fibrosarcoma are also seen [5]. The incidence of malignant transformation ranges from about 0.5% in the monostotic form to about 4% in patients with the polyostotic form [8]. No cases of secondary malignancy were detected in our patients.

#### 5. CONCLUSION

Fibrous dysplasia is relatively common in our environment. The age at diagnosis, gender distribution and site of diagnosis correlate with published literature from other parts of the world.

#### CONSENT

It is not applicable.

#### ETHICAL APPROVAL

As per international standard or university standard written ethical approval has been collected and preserved by the author(s).

#### ACKNOWLEDGEMENT

We wish to appreciate all members of staff of the department of records and histopathology department at the Jos University Teaching Hospital.

#### COMPETING INTERESTS

Authors have declared that no competing interests exist.

#### REFERENCES

1. Seban A, Blein E, Perez S, Seban B. Cranio-Facial Fibrous Dysplasia: A case report of a conservative treatment in a monostotic form associated with an orthodontic management and a bone graft of the non-lytic bone area for dental implant rehabilitation. *J Clin Adv Dent.* 2019;3: 018-022.
2. Pinto MD, Braz GG, Santos RG, Polido D, Paixão JR, de Melo SH et al. Fibrous Dysplasia in Maxillary Bone: Case Report. *Int J Oral Dent Health.* 2018;4(2):072. DOI.org/10.23937/2469-5734/1510072
3. Pontes-Madruga T, Filgueiras HV, Silva DM, Silva LS, Testa JR. Fibrous dysplasia: rare manifestation in the temporal bone. *Braz J Otorhinolaryngol;* 2020.

- Available: <https://doi.org/10.1016/j.bjorl.2020.05.027>
4. Siegal GP, Bianco P, Dal Cin P. Fibrous Dysplasia. In: Fletcher CDM, Bridge JA, Hogendoorn PCW, Mertens F (eds). WHO Classification of tumours of soft tissue and bone. 4th ed. Lyon: IARC press. 2013;352-53.
  5. Lee JS, FitzGibbon EJ, Chen YR, Kim HJ, Lustig LR, Akintoye SO. et al. 2012. Clinical guidelines for the management of craniofacial fibrous dysplasia. Orphanet Journal of Rare Diseases. 2012;7(Suppl 1.):S2.  
DOI:10.1186/1750-1172-7-S1-S2
  6. Rosai J. Bone, Joints. In: Rosai and Ackermans Surgical Pathology, 10th Edition. China Elsevier. 2011;2:2013 – 104.
  7. Horvai A. Bones, Joints and soft tissue tumors. In: Kumar V Abbas AK, Aster JC (eds.) Robins and Cotran Pathologic basis of disease. 9th Ed; Philadelphia: Elsevier Saunders. 2015;1180-226.
  8. Vikram K, Akhil S. Polyostotic Fibrous Dysplasia: A Case Report. JOJ Case Stud. 2017;3(1): 555601.  
DOI: 10.19080/003JOJCS.2017.03.555601
  9. Rahman AMA, Madge SN, Billing K, Anderson PJ, Leibovitch I, Selva D, David D. Craniofacial fibrous dysplasia: clinical characteristics and long-term outcomes. Eye. 2009;23:2175-2181.
  10. Kanasirska CRP, Kanasirski N, Dinkova CA. Fibrous dysplasia in the maxillomandibular region- case report. Jofl MAB. 2010;16(4):10-13.  
DOI: 10.5272/jimab.1642010\_10-13.
  11. Riddle ND, Bui MM. Fibrous dysplasia. Arch Pathol Lab Med. 2013;137:134–138.  
DOI: 10.5828.arpa/2012.0013-RS
  12. Mohan H, Mittal P, Mundi I, Kumar S. Fibrous dysplasia of bone: A clinicopathologic review. Pathology and Laboratory Medicine International. 2011;3:31–42.
  13. Chong VFH, Khoo JBK, Fan Y. Fibrous Dysplasia Involving the Base of the Skull. AJR. 2002;178:717-720.
  14. Assiri KI. Monostotic Fibrous Dysplasia Involving the Mandible: A Case Report. SAGE Open Medical Case Reports. 2020;8:1-4.  
DOI.org/10.1177/2050313X20936954.
  15. Abdulkareem FB, Eyasan SU, Akinde OR, Ezembakwe ME, Nnodu OE. Pathological study of bone tumors at National Orthopaedic Hospital, Lagos Nigeria. WAJM. 2020;26(4): 306-11.
  16. Lasebikan OA, Nwadinigwe CU, Onyegbule EC. Pattern of bone tumours seen in a regional Orthopaedic Hospital in Nigeria. NJM. 2014;23(1):46-50.
  17. Mohammed A, Isa HA. Patterns of primary tumours and tumour-Like lesions of bone in Zaria, Northern Nigeria: A review of 127 cases. WAJM. 2007;26(1):37-41.

© 2021 Akpa et al.; This is an Open Access article distributed under the terms of the Creative Commons Attribution License (<http://creativecommons.org/licenses/by/4.0>), which permits unrestricted use, distribution, and reproduction in any medium, provided the original work is properly cited.

*Peer-review history:*

*The peer review history for this paper can be accessed here:*  
<http://www.sdiarticle4.com/review-history/69355>