

## **Immunohistochemical Characterization of Genes Expressed in Leiomyoma using Ki67 and P53 in Patient Attending Niger Delta University Teaching Hospital**

**E. F. Eruvwahwe<sup>1</sup>, E. U. Eric<sup>2\*</sup>, O. G. E. Alaba<sup>3</sup> and M. B. Deelee<sup>2</sup>**

<sup>1</sup>*Federal Medical Center, Asaba, Delta State, Nigeria.*

<sup>2</sup>*Department of Medical Laboratory Sciences, Niger Delta University, Wiberforce Island, Bayelsa State, Nigeria.*

<sup>3</sup>*Department of Medical Laboratory Sciences, University of Abuja Teaching Hospital, Abuja Nigeria.*

### **Authors' contributions**

*This work was carried out in collaboration among all authors. Author EUE designed the study, performed the statistical analysis, wrote the protocol and wrote the first draft of the manuscript. Authors EFE and OGEA managed the analyses of the study. Author MBD managed the literature searches. All authors read and approved the final manuscript.*

### **Article Information**

DOI: 10.9734/JCTI/2021/v11i330154

#### Editor(s):

(1) Dr. William C. S. Cho, Queen Elizabeth Hospital, UK.

(2) Dr. Pandiaraja J., Shree Devi Hospital, India.

(3) Dr. Nicole D. Riddle, Tampa General Hospital, USA.

#### Reviewers:

(1) Anonymous, Italy.

(2) Sudhamani S., D. Y. Patil University, India.

(3) P. Jayanthi, Azeezia College of Dental Sciences and Research Kollam, India.

Complete Peer review History: <http://www.sdiarticle4.com/review-history/66368>

**Original Research Article**

**Received 03 February 2021**

**Accepted 07 April 2021**

**Published 12 June 2021**

### **ABSTRACT**

**Objectives:** This study aimed to investigate the expressions of p53 and ki67 genes in the characterization of leiomyomas.

**Materials:** Fifty (50) Paraffin embedded tissue blocks were selected from the department of Histopathology, Niger Delta University Teaching Hospital, Okolobri from January 2011 to August 2019. The histological characterization and morphological evaluation were defined using the routine Hematoxylin and Eosin staining method. Immunostaining was done for p53 and ki67 using the manufacturers antibodies.

\*Corresponding author: Email: [drericuchenna@gmail.com](mailto:drericuchenna@gmail.com);

**Results:** A direct correlation between age and the expression of the p53 gene was also made in this study. It was observed that in patients within the ages of 50-59 and 60-69, there was markedly no expression of the p53 gene whereas in patients within the ages of 20-29, there was still some level of expression (20%) and ages 30-39 (80%) and finally 40-49 (10%). There was no expression (0.0%) of Ki-67 in uterine leiomyomas across all age groups.

**Conclusion;** This study therefore has suggested that based on the percentage of expression, it can rightly be inferred that the p53 gene is a good indicator in the immune-histochemical characterization of leiomyomas as it has good sensitivity and good prognosis as opposed to Ki67.

*Keywords: Leiomyoma; P53; immunohistochemistry; uterus; Ki67.*

## 1. INTRODUCTION

The most common female genital tract neoplasms are uterine smooth muscle tumors. They could broadly be classified into the following: leiomyomas (LMs), smooth muscle tumors of uncertain malignant potential (STUMP) and leiomyosarcomas (LMS) [1]. The most common type, LM, occurs in nearly 40% of women older than 35 years. Uterine LMSs are relatively rare smooth muscle tumors and account for about one third of uterine sarcomas and 1.3% of all uterine malignancies [2].

Uterine smooth muscle tumors could either be benign or malignant depending on certain factors such as combination of microscopic features including the presence and type of necrosis, the degree of cytologic atypia, the mitotic activity, and the relationship of the tumor to surrounding normal structures. However, a small number of uterine smooth muscle tumors constitute difficult diagnostic challenges. Considering some morphological features, some variants of LM, such as cellular leiomyoma, atypical leiomyoma (leiomyoma with bizarre nuclei) (ALM) and mitotically active leiomyoma can mimic malignancy in one or more aspects. In cases where some smooth muscle tumors cannot be classified as either benign or malignant, based on histopathological criteria they are diagnosed as the smooth muscle tumor of uncertain malignant potential (STUMP). This term is used when there is some significant doubt about the failure probability associated with a particular combination of microscopic features. [2,3].

Uterine leiomyoma are monoclonal tumors and approximately 40 to 50% show karyotypically detectable chromosomal abnormalities. When multiple leiomyoma are present they frequently have unrelated genetic defects. Specific mutations of the MED12 protein have been noted in 70 percent of leiomyoma [4].

As a result of variations in interpretation and subjective identifications of some microscopic

features (mitotic figures, type of necrosis), there has been an introduction of potential diverse diagnostic criteria for uterine smooth muscle tumors. Few reports investigated steroid receptor expression in uterine smooth muscle tumors. It was thus observed that there were significant differences of PR expression between uterine LM, STUMP and LMS [5-8].

Immunohistochemical staining is widely used in the diagnosis of abnormal cells such as those found in cancerous tumors. Specific molecular markers are characteristic of particular cellular events such as proliferation or cell death (apoptosis) [9]. Tumor protein p53 (TP53), also known as p53, cellular tumor antigen p53, phosphoprotein p53, tumor suppressor p53, antigen NY-CO-13, or transformation-related protein 53 (TRP53), is any isoform of a protein encoded by homologous genes in various organisms, such as TP53 (humans) and Trp53 (mice) gene.

There is little information currently available regarding the content of p53 protein in human leiomyomas. However, in a study carried out by Zhijian *et al* [10] to elucidate the p53 protein content in human leiomyomas and its regulation by sex steroid hormones, the content of p53 protein in leiomyomas was examined by immunohistochemical staining and Western blot analysis in comparison with that in the adjacent normal myometrium or leiomyoma specimens from GnRH agonist-treated patients. Immunohistochemical staining and Western blot analysis revealed that p53 protein content was highest in leiomyomas treated with GnRH agonist for 16 weeks, lower in leiomyomas in the secretory-P4-dominated phase, and lowest in leiomyomas in the proliferative, E2-dominated phase of the menstrual cycle. There was no difference in p53 content between leiomyomas and the adjacent normal myometrium.

Antigen Ki-67 also known as Ki-67 or MKI67 is a protein that in humans is encoded by the MKI67

gene (antigen identified by monoclonal antibody Ki-67).

The Ki-67 protein is a cellular marker for proliferation. It is strictly associated with cell proliferation. During interphase stage of cell division, the Ki-67 antigen can be exclusively detected within the cell nucleus, whereas in mitosis most of the protein is relocated to the surface of the chromosomes. Ki-67 protein is present during all active phases of the cell cycle (G1, S, G2, and mitosis), but is absent in resting (quiescent) cells (G0). Cellular content of Ki-67 protein markedly increases during cell progression through S phase of the cell cycle [9].

Ki-67 is an excellent marker to determine the growth fraction of a given cell population. The fraction of Ki-67-positive tumor cells (the Ki-67 labeling index) is often correlated with the clinical course of cancer. Expression of Ki-67, which is regarded as an indicator of biological aggressiveness has been observed in different human malignancies [11] as well as in uterine LMS [8]. In accordance with these studies, it was observed that there was a significant expression of Ki-67 in uterine LMS. However, until recently, only two authors have analyzed differences between the Ki-67 expression in leiomyomas, STUMP and LMS together in their studies [8].

The aim of this research was to investigate the expressions of p53 and ki67 genes in the characterization of leiomyomas.

## **2. MATERIALS AND METHODOLOGY**

### **2.1 Study Area**

The study was performed at Niger Delta University Teaching Hospital, Okolobri, Bayelsa State. The hospital serves as a referral centre in Bayelsa State and equally serves as a training institution for medical and allied medical science students. Bayelsa state is located within lat. 4.15N and lat. 5.23 south and long. 5.221 and 6.51 East of the equator, bounded by the Atlantic ocean by the South of Nigeria. Bayelsa State has the highest collection of the Ijaw tribes in Nigeria. The state is the second largest producer of crude oil in Nigeria and has the largest gas reserve and oil well. Her major occupation is fishing and civil service.

### **2.2 Sample Collection**

Paraffin embedded tissue blocks were collected from the department of Histopathology, under the

supervision of the laboratory scientist in charge at the Niger Delta University Teaching Hospital, Okolobri from August 2019.

### **2.3 Sectioning of Block**

The blocks were sectioned, using a microtome to section the tissues into 3-5 microns that is suitable for preparing a slide out of it.

### **2.4 Slide Preparation**

The tissues are prepared on a slide by adhering the tissues to the slide properly by picking it from the hot water bath.

### **2.5 Sample Size**

A total of fifty (50) slides of Leiomyoma tissues were collected of different ages.

### **2.6 Methodology**

The histological characterization and morphological evaluation were defined using the routine Hematoxylin and Eosin staining method. Immunostaining was done for p53 and ki67 using the manufacturers antibodies.

Color development and background staining was visualized using the 3,3-diaminobenzidine chromogen and hematoxylin counter stain respectively. Appropriate negative controls for immunostaining were prepared by eliminating the primary antibody step. A positive control which consisted of formalin-fixed, paraffin-embedded specimen of human breast carcinoma was collected from the department of Histopathology, under the supervision of the laboratory scientist in charge at the Niger Delta University Teaching Hospital, Okolobri.

The samples for the study were randomly assigned into four groups of individuals and the extent of the percentage of genes of individual gene. The different histochemical stains are used to stain each group to characterize the various moles and gene expressed.

### **2.7 Protocol**

1. The processed tissues were sectioned at 2 microns on Leica rotary microtome and placed on the hot plate at 70°C for 1 hour.
2. Sections were brought down to water by passing the sections on 2 changes of

- xylene, then 3 changes of descending grades of Alcohol (Absolute 1, Absolute @, 95%, 80%, 70% and finally to water.
3. Antigen retrieval was performed on the sections by heating them on a citric acid solution of pH 6.0 using the microwave plate at 100°C for 15 minutes.
  4. The sections were equilibrated gradually with cool water to displace the hot citric acid for at least 15 minutes for the section to cool.
  5. Peroxidase blocking was done on the sections by simply covering section with 3% hydrogen peroxide (H<sub>2</sub>O<sub>2</sub>) for 15 minutes.
  6. Sections were washed with phosphate Buffered saline (PBS) and protein blocking performed using Avidin for 15 minutes.
  7. Sections were washed with PBS and endogenous biotin blocked using biotin for 15 minutes.
  8. After washing with PBS, sections were incubated with the respective diluted primary antibody (Rabbit monoclonal [TP53\2092R] to p53 antibody) in 1:100 for 60 minutes.
  9. Excess antibody was washed off with PBS and secondary antibody (LINR) were applied on the section for 15 minutes.
  10. Section were washed and labeled and the horseradish peroxidase (HRP) were applied on the section for 15 minutes.
  11. A working DAB solution was prepared by mixing 1 drop (20 microns) of the DAB chromogen to 1ml of DAB substrate. This working solution is applied on sections after washing off the HRP with PBS for 5 minutes, the brown reaction begins to

appear at this moment especially for a positive reaction.

## 2.8 Observation

Cells with specific brown color in the cytoplasm, cell membrane nuclei depending on the antigenic sites are considered to be positive. The hematoxylin stained cells without any form of brown color are scored negative. Non-specific binding/brown artefacts on cells and connective tissue are disregarded.

## 2.9 Statistical Analysis

Data was analyzed using SPSS vs 25 values were presented as mean ±SD and percentage.

## 3. RESULTS

A total of fifty (50) slides of Leiomyoma tissues were collected across different ages (20 - 69) and analyzed. The results are presented in photomicrographs and tables.

## 4. DISCUSSION AND CONCLUSION

### 4.1 Discussion

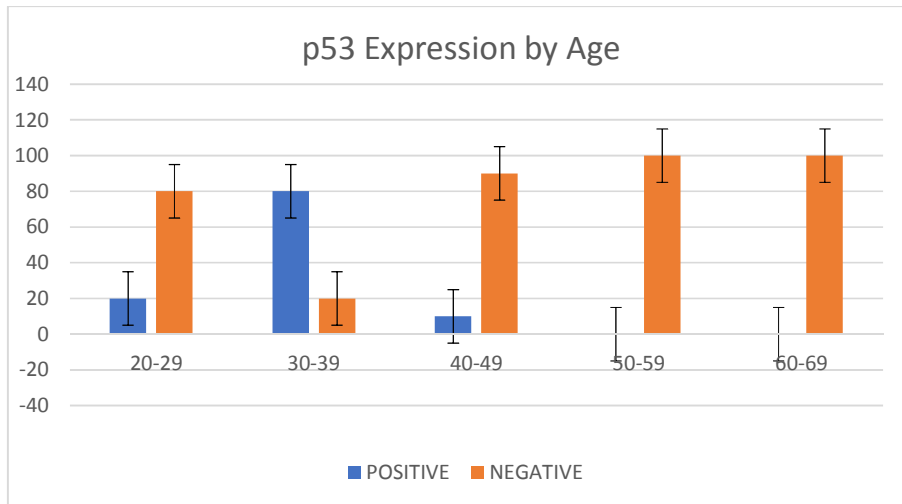
A direct correlation between age and the expression of the p53 gene was made in this study. It was observed that in patients within the ages of 50-59 and 60-69, there was markedly no expression of the p53 gene whereas in patients within the ages of 20-29, there was still some level of expression (20%) and ages 30-39 (80%) and finally 40-49 (10%).

**Table 1 Showing p53 % expression by age**

Age distribution	Positive	Negative
20-29	20%	80%
30-39	80%	20%
40-49	10%	90%
50-59	0%	100%
60-69	0%	100%

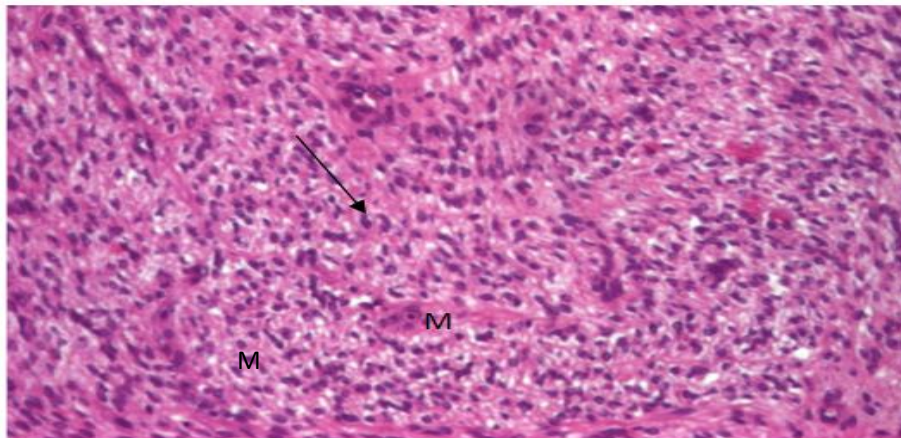
**Table 2 Showing Ki67 % expression by age**

Age distribution	Positive	Negative
20-29	0%	100%
30-39	0%	100%
40-49	0%	100%
50-59	0%	100%
60-69	0%	100%

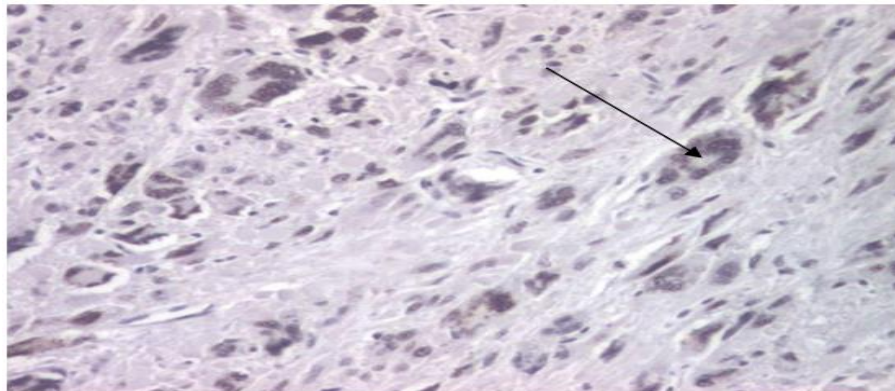


**Fig. 1. Frequency distribution of p53 Expression by Age**

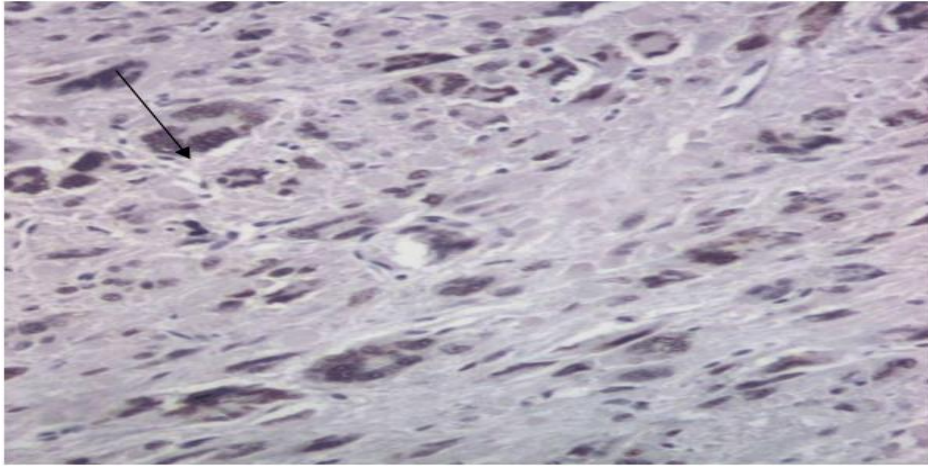
**PLATES**



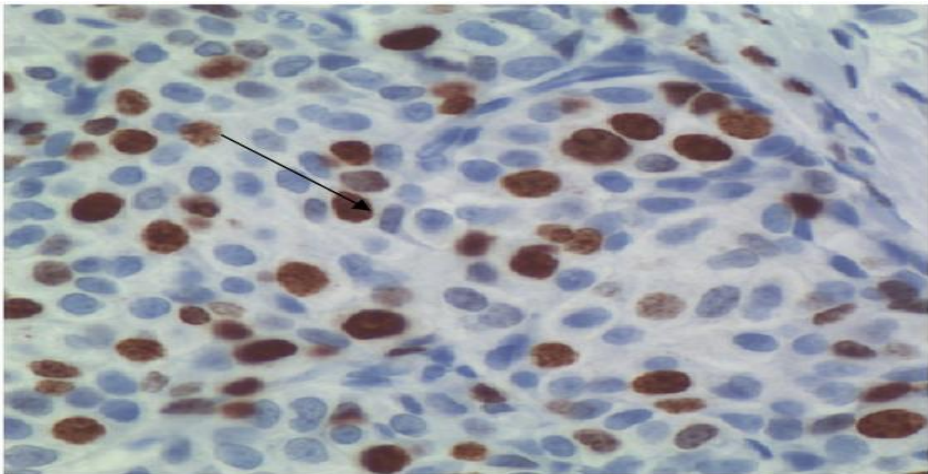
**Plate 1. Shows the morphology of leiomyoma,whorl pattern of smooth muscle (M),Arrow shows variable lymphocytes**



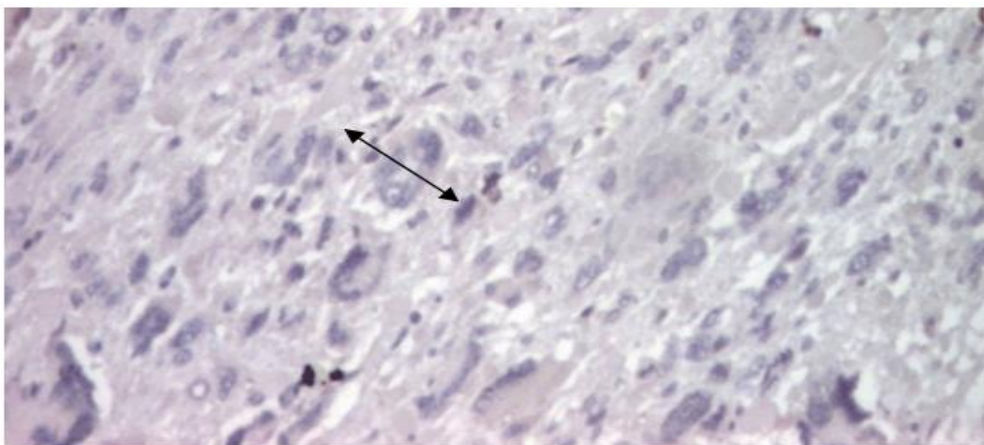
**Plate 2. Shows the morphology of leiomyoma positive for H & E (X40)**



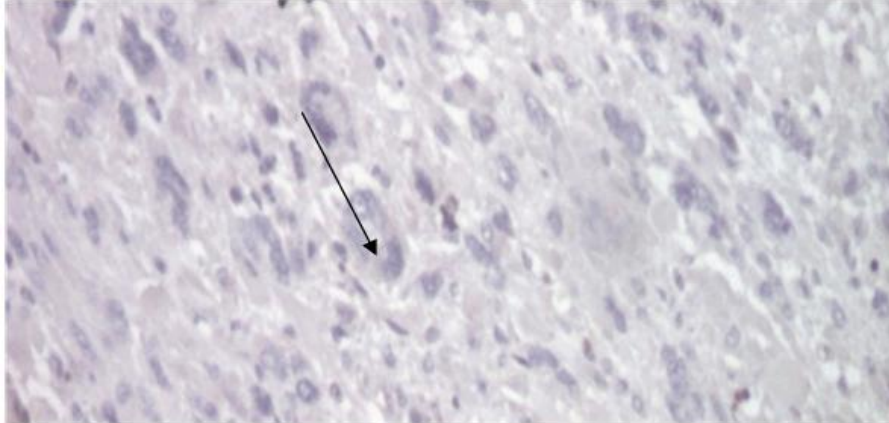**Plate 3. Shows the morphology of leiomyoma positive for p53(X40)**



**Plate 4. Shows the morphology of breast carcinoma positive for p53 [positive control](X40)**



**Plate 5. Shows the morphology of leiomyoma negative for Ki67 (X40)**



**Plate 6. Shows the morphology of leiomyoma negative for Ki67 (X40)**

Leiomyoma is a benign smooth muscle tumor that very rarely becomes cancer (0.1%). Majority of uterine smooth muscle tumors can be classified into benign or malignant. The basis of such classification depends on a combination of microscopic features including the presence and type of necrosis, the degree of cytologic atypia, the mitotic activity, and the relationship of the tumor to surrounding normal structures. In a study carried out by Zhijian et al., [12], to determine the p53 protein content in human leiomyomas, it was observed that there was no difference in p53 content between leiomyomas and the adjacent normal myometrium. This was quite intriguing because usually, p53 protein can be highly unstable in most human cancers [13]. When p53 is normal, it functions as a protection by guarding the genome against somatic mutations that may initiate cancer. On the other hand, when it is inactivated, it is unable to prevent increased genetic instability and lacks its tumor suppressing function.

In this present study, it was observed that in a majority of cases there were mutations of the p53 gene in patients with Leiomyoma therefore confirming a study carried out by Blagosklonny [14] where he stated that if the p53 gene is damaged, tumor suppression is severely reduced. He observed that in more than 50% of human tumors there is a mutation or deletion of the p53 gene. In this study, there was a direct relationship between age and the expression of the p53 gene. It was observed that patients within the ages of 50-59 and 60-69, there were markedly no expression of the p53 gene whereas in patients within the ages of 20-29, there was still some level of expression (20%) and ages 30-

39 (80%) and finally 40-49 (10%). This may suggest that with an advance in age, there may be a higher chance for mutation or deletion of the p53 gene and thus predispose an individual to development of cancer from Leiomyoma as a result of unsuppressed tumor growth. This supports the study of Rammeh-Rommani et al., [2] where it was stated that Leiomyoma's are the most common type of uterine smooth muscle tumors which occurs in nearly 40% of women older than 35 years.

Ki-67 antigen is a nuclear protein expressed in the active parts of the cell cycle from the late phase S, and more in G2 and M, but is absent in G0 [15]. Thus, Ki-67 is regarded as an indicator of cell proliferative activity and, hence, biological aggressiveness [11]. An increased Ki-67 expression has been observed in uterine leiomyosarcomas (LMS), compared with benign leiomyomas [8,16,17]. However, there has only been few studies where the extent of Ki-67 expression in uterine leiomyomas, smooth muscle tumors of uncertain malignant potential (STUMP) and LMS have been carried out [8,17]. In a study carried out by Klaus et al. [18], their study revealed that the expression of Ki-67 in uterine LMS was significantly higher than that in leiomyomas. However, in this present study, there was no expression (0.0%) of Ki-67 in uterine leiomyomas. This suggests that there was no cell proliferation activity in uterine leiomyomas.

#### **4.2 Conclusion**

This study therefore has suggested that based on the percentage of expression, it can rightly be inferred that the p53 gene is a good indicator in

the immune-histochemical characterization of leiomyomas as it has good sensitivity and good prognosis but in Ki-67 expression (0.0 %.), it shows that Ki-67 cannot be used as a reliable tool in the characterization of leiomyomas as it has poor sensitivity with a poor prognosis.

## CONSENT AND ETHICAL APPROVAL

As per international standard or university standard guideline participant consent and ethical approval has been collected and preserved by the authors.

## COMPETING INTERESTS

Authors have declared that no competing interests exist.

## REFERENCES

1. Zaloudek CJ, Hendrickson MR, Soslow RA. Mesenchymal tumors of the uterus. Blaustein's pathology of the female genital tract. Edited by: R. Kurman RJ, Ellenson LH, Ronnett BM. Springer New York. 2011;453-527.
2. Rammeh-Rommani S, Mokni M, Stita W, Trabelsi A, Hamissa S, Sriha B, Tahar-Yacoubi M. Journal of Gynecology and Obstetrics Biological Reproduction. 2005;34:568-7.
3. Ünver NU, Acikalin MF, Öner Ü, Ciftci E, Ozalp SS, Colak E. Differential expression of P16 and P21 in benign and malignant uterine smooth muscle tumors. Arch Gynecology Obstetrics. 2011;284 (2):483-90.
4. Makinen N, Mehine M, Tolvanen J, Kaasinen E, Li Y, Lehtonen HJ, Gentile M, Yan J, Enge M, Taipale M, Aavikko M, Katainen R, Virolainen E, Bohling T, Koski TA, Launonen V, Sjoberg J, Taipale J, Vahteristo P, Aaltonen LA. MED12, the mediator complex subunit 12 gene, is mutated at high frequency in uterine leiomyomas. Science. 2011;334(6053):252-5.
5. O'Neill C, McBride H, Connolly L, McCluggage W. Uterine leiomyosarcomas are characterized by high p16, p53 and MIB1 expression in comparison with usual leiomyomas, leiomyoma variants and smooth muscle tumours of uncertain malignant potential. Histopathology. 2007;50(7):851-8.
6. Gökaslan H, Turkeri L, Kavak ZN, Eren F, Sismanoglu A, Ilvan S. Differential diagnosis of smooth muscle tumors utilizing p53, pTEN and Ki-67 expression with estrogen and progesterone receptors. Gynecol Obstet Invest. 2005;59:36-40.
7. Bodner K, Bodner-Adler B, Kimberger O, Czerwenka K, Mayerhofer K. Estrogen and progesterone receptor expression in patients with uterine smooth muscle tumors. Fertil Steril. 2004;81:1062-6.
8. Mittal K, Demopoulos RI. MIB-1 (Ki-67), p53, estrogen receptor, and progesterone receptor expression in uterine smooth muscle tumors. Human Pathology. 2001;32:984-7.
9. Ramos-Vara JA. Technical Aspects of Immunohistochemistry. Veterinary Pathology. 2005;42(4): 405-426.
10. Zhijian G, Hiroya M, Satoshi N, Osamu K, Takeshi M (). p53 Tumor Suppressor Protein Content in Human Uterine Leiomyomas and its Down-Regulation by 17β-Estradiol. The Journal of Clinical Endocrinology & Metabolism. 2002;87(8):3915-3920
11. Layfield LJ, Liu K, Dodge R, Barsky SH. Uterine smooth muscle tumors: utility of classification by proliferation, ploidy, and prognostic markers versus traditional histopathology. Arch Pathol Lab Med. 2000;124:221-7.
12. Zimmermann A, Bernuit D, Gerlinger C, Schaefer M, Geppert K. Prevalence, symptoms and management of uterine fibroids: An international internet-based survey of 21,746 women. BMC women's health. 2012;12(1):6-8.
13. Zalondek CJ, Hendricksen CJ. Mesenchymal tumors of the uterus. Blaustein's pathology of the female genital tract. Edited by: Kurman RJ. Spinger, New York. 2002;561-615.
14. Blagosklonny VM. P53;An ubiquitous target of anticancer drugs. International Journal of Cancer. 2001;98(2):161-166.
15. Cattoretti G, Becker MHG, Key G, Duchrow M, Schluter C, Galle J. Monoclonal antibodies against recombinant parts of the Ki-67 antigen (MIB 1 and MIB 3) detect proliferating cells in microwave processed formalin-fixed paraffin sections. Journal of Pathology. 1992;168: 357-63.



16. Chou CY, Huang SC, Tsai YC, Hsu KF, Huang KE. Uterine leiomyosarcoma has deregulated cell proliferation, but not increased microvessel density compared with uterine leiomyoma. *Gynecology and Oncology*. 1997;65:225–31.
17. Zhai YL, Nikaido T, Shizawa T, Orie A, Fujii S. Expressions of cyclins and cyclin dependent kinases in smooth muscle tumors of the uterus. *International Journal for Cancer*. 1999;84:244-50.
18. Klaus Bodner, Barbara B, Oliver K, Klaus C, Klaus M. Estrogen and progesterone receptor expression in patients with uterine smooth muscle tumors. *Fertility and Sterility*. 2009;8(4):1062-1066.

---

© 2021 Eruvwahwe et al.; This is an Open Access article distributed under the terms of the Creative Commons Attribution License (<http://creativecommons.org/licenses/by/4.0>), which permits unrestricted use, distribution, and reproduction in any medium, provided the original work is properly cited.

*Peer-review history:*  
*The peer review history for this paper can be accessed here:*  
<http://www.sdiarticle4.com/review-history/66368>