

## **A gastrointestinal Stromal Tumor of the Small Bowel Presenting as an Acute Peritonitis: A Case Report**

**Amal Hajri<sup>1</sup>, Karim Yaqine<sup>1\*</sup>, Anas Elwassi<sup>1</sup>, Driss Erguibi<sup>1</sup>, Rachid Boufettal<sup>1</sup>, Saad Rifki ElJai<sup>1</sup> and Farid Chehab<sup>1</sup>**

<sup>1</sup>*Department of Visceral Surgical, University of Hassan II Casablanca, CHU Ibn Rochd, Casablanca, Morocco.*

### **Authors' contributions**

*This work was carried out in collaboration among all authors. Author AH designed the study, collected all information wrote the first draft of the manuscript and the end manuscript. Authors KY, AE, DE, RB, SRE and FC managed the literature searches and aided with the final manuscript. All authors read and approved the final manuscript.*

### **Article Information**

DOI: 10.9734/JCTI/2021/v11i430161

#### Editor(s):

- (1) Dr. William CS Cho, Queen Elizabeth Hospital, China.
- (2) Dr. Pandiaraja. J, Shree Devi Hospital, India.
- (3) Dr. Bing Yan, Hainan Branch of PLA General Hospital, China.
- (4) Dr. Sung-Chul Lim, Chosun University, South Korea.
- (5) Dr. Giulio Tarro, Foundation T. & L. de Beaumont Bonelli for cancer Research, Italy.

#### Reviewers:

- (1) M. Gokul, Kalasalingam University, India.
  - (2) Abeer Shaker Elmoursy Ali, Umm Al Qura University, Saudi Arabia.
- Complete Peer review History: <http://www.sdiarticle4.com/review-history/69626>

**Case Report**

**Received 08 July 2021**  
**Accepted 13 September 2021**  
**Published 08 November 2021**

### **ABSTRACT**

**Introduction:** Gastrointestinal stromal tumors (GISTs) are the most common mesenchymal tumors in the gastrointestinal tract, GISTs of the small bowel presenting as an acute peritonitis are rare, which necessitates emergency surgery.

**Presentation of Case:** A 44-year-old women presented with severe abdominal pain and nausea. Physical examination revealed a tenderness and muscular defense around the lower abdomen. Laboratory data showed an elevated white blood cell count and C-reactive protein level. An enhanced computed tomography (CT) scan showed a 8 × 10 cm cystic mass in the lower abdomen, which contained air. Emergency laparotomy showed a giant perforated tumor that arose from the ileum, the tumor and affected segment of ileum were resected. the tumor was diagnosed as GIST in low-risk category, and imatinib mesylate was initiated, The patiente had an uneventful postoperative course and remains well.

\*Corresponding author: Email: [yaqine.karim@gmail.com](mailto:yaqine.karim@gmail.com);

**Discussion and Conclusion:** Such rare cases can be diagnosed and treated properly with careful clinical evaluation. Computed tomography (CT) is the gold standard for imaging that is used to characterize any abdominal mass. Surgical resection is still the first-line treatment for patients with primary localized and resectable small bowel GIST and adjuvant chemotherapy with imatinib mesylate is indicated in patients with high-risk small bowel GIST.

*Keywords: Gastrointestinal stromal tumor; acute peritonitis; emergency surgery.*

## 1. INTRODUCTION

Gastrointestinal stromal tumors (GIST) are the most common primary mesenchymal tumor located in the gastrointestinal (GI) tract. They may occur anywhere along GI tract, the most common localization of GIST is the stomach, followed by the small intestine [1]. GIST are derived from interstitial cells of Cajal, which play an important role in autonomous gastrointestinal peristalsis [2], A small percentage may cause acute symptoms requiring urgent surgical intervention [3]. GISTs of the small bowel presenting as an acute peritonitis are rare, which necessitates emergency surgery. This work has been reported in line with the SCARE criteria [4].

## 2. CASE PRESENTATION

A 44-year-old women admitted in the emergency room due to severe abdominal pain and nausea. Physical examination revealed a fever of 38°C blood pressure (110/60 mmHg) and heart rate (110 beats/min), tenderness and muscular defense around the lower abdomen. Laboratory data showed white blood cell count of 15010/mm<sup>3</sup> and C-reactive protein of 323 mg/L.

An enhanced computed tomography (CT) scan showed a 8 × 10 cm cystic mass in the lower abdomen, which contained air. No other visceral abnormalities were found (Fig. 1). A combination therapy that includes systemic administration of antibiotics and an emergent exploratory laparotomy was performed. the exploration of abdominal cavity showed a moderate quantity of free fluid that was collected for the culture test and a giant perforated tumor that arose from the ileum wall that was located 250 cm from the ligament of Treitz. The tumor and affected segment of ileum were resected (Fig. 2) and an ileostomy was performed. The histopathology of the small bowel specimen showed a mass with 12×8 cm in size, without margin involvement (R0). The mass was diagnosed accordingly as GIST in low-risk category, the immunohistochemical staining showed that the tumor was positive for c-kit and CD117, α-smooth muscle actin and to S-100 protein.

The patiente was discharged from hospital on the 3th postoperative day and has been treated with imatinib in the outpatient clinic without any medical problems, reversal of ileostomy was performed 1 month later.

## 3. DISCUSSION

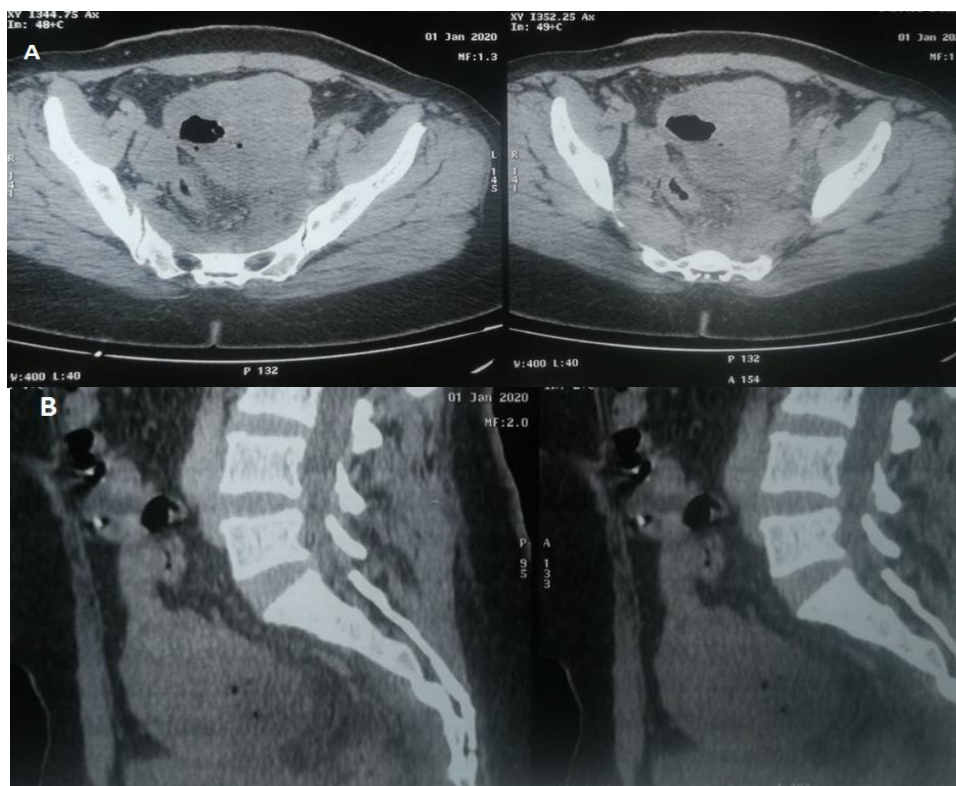
Gastrointestinal stromal tumors (GISTs) are specific mesenchymal tumors of the gastrointestinal (GI) tract and a majority of these tumors occur in the stomach (60%) and the small intestine (30%) [5]. Attention should be paid to small intestinal GISTs because they infrequently manifest abdominal emergencies such as bowel obstruction, tumor rupture, perforation, and intratumoral abscess formation [1]. Cases of the small bowel GIST presenting as an acute peritonitis as in our case are also rare.

The development of malignant GIST requires the transformation of the interstitial cells of Cajal, pacemakers of the GI tract, to a malignant phenotype through activating or gain of function mutations in the *c-KIT* proto-oncogene. GIST are spindle cell neoplasms that usually retain the ultrastructural characteristics of smooth muscle cells, but have immunohistochemical staining for *c-KIT*, *CD-34*, smooth muscle actin, desmin and S-100. Approximately 70% of GIST are spindle cell type neoplasms, the minority are epithelioid (20%) or mixed cell type (10%) [6]. Mitotic index calculated by counting the number of mitoses per 50 high-power fields is an important indicator of proliferative activity and prognosis of GIST. the availability of a KIT and PDGFRA tyrosine kinase inhibitor, imatinib mesylate, has dramatically changed treatment strategies for metastatic or unresectable GISTs [7].

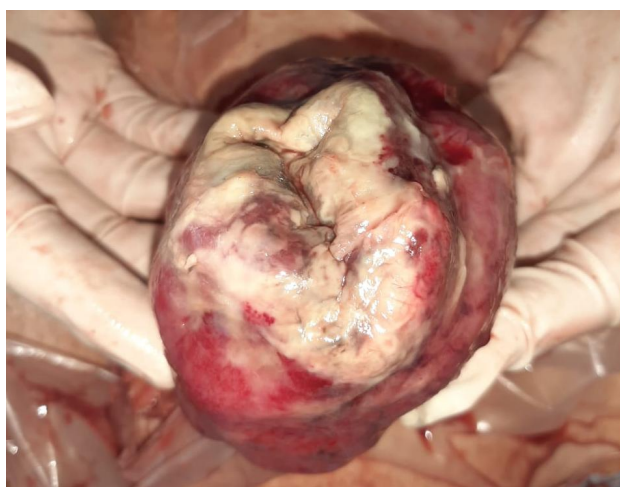
Computed tomography (CT) is the gold standard for imaging that is used to characterize any abdominal mass in addition to assessing its extent and the presence/absence of disease at a distance (GIST metastasize more frequently to the liver, omentum, and peritoneal cavity). Therefore, with suspicion of a tumor in the digestive tract, an initial CT scan should be done

[8]. Magnetic resonance imaging (MRI) is an acceptable alternative and more accurate than CT for delineating rectal GISTs and in detecting liver metastasis. Positron emission tomography (PET) can be used for both initial evaluation and trending the disease's progression that may be

useful for detecting unapparent metastases or an otherwise unknown primary site and determining the response to neoadjuvant targeted therapy. PET scans usually indicate tumor responsiveness to imatinib mesylate within days to weeks of induction therapy [6].



**Fig. 1. (A, B) Enhanced computed tomography (CT) scan of the abdomen revealing a cystic mass in the lower abdomen, which contained air**



**Fig. 2. Specimen of a gastrointestinal stromal tumor (GIST) of the small bowel**

capsule endoscopy is a safe and painless method for mucosal imaging of the small bowel double-balloon endoscopy enables endoscopic inspection of the entire small bowel with the ability to take biopsy samples and with the potential to administer localized therapy [9].

In our case (CT) scan showed a 8 × 10 cm cystic mass in the lower abdomen, which contained air Surgical resection is still the most effective and the only potentially curative treatment when possible for GISTs to date. For small intestinal GISTs, partial small bowel resection with the tumor is the standard procedure [10]. GISTs only require the achievement of R0 resection without violating the capsule of the mass, and lymphadenectomy is not necessary [11]. Laparoscopic surgery has the potential advantage of requiring smaller incisions, less bowel manipulation, shorter hospital stay, lower blood loss, and less pain medication requirements compared with open surgery [3]. In this particular case of acute diffuse peritonitis emergency laparotomy was performed to excise the tumor and affected segment of ileum.

Results showed that imatinib mesylate is effective as an adjuvant treatment following complete resection To delay or prevent relapse and prolong patient survival, in patients with high-risk small bowel GIST, and is recommended for 3 years [9]. Our patiente received adjuvant therapy based on imatinib.

#### 4. CONCLUSION

There were few reports of GISTs of the small bowel presenting as an acute peritonitis, We present a rare case of an acute peritonitis caused by the spontaneous rupture of a large GIST of the ileum in whom emergency surgery was necessary

#### CONSENT

As per international standard, patient's consent has been collected and preserved by the authors.

#### ETHICAL APPROVAL

As per international standard, written ethical approval has been collected and preserved by the author(s).

#### COMPETING INTERESTS

Authors have declared that no competing interests exist.

#### REFERENCES

1. Ito S, Tsuchitani Y, Kim Y, Hashimoto S, Miura Y, Uemura T, et al. A gastrointestinal stromal tumor of the jejunum presenting with an intratumoral abscess: A case report and a literature review. *International Journal of Surgery Case Reports*. 2018;48:65-8.
2. Waidhauser J, Bornemann A, Trepel M, Märkl B. Frequency, localization, and types of gastrointestinal stromal tumor-associated neoplasia. *WJG*. 14 août. 2019;25(30):4261-77.
3. Morrison JE, Hodgdon IA. Laparoscopic Management of Obstructing Small Bowel GIST Tumor. *JLS*. 2013;17(4):645-50.
4. Agha RA, Borrelli MR, Farwana R, Koshy K, Fowler AJ, Orgill DP, et al. The SCARE 2018 statement: Updating consensus Surgical Case Report (SCARE) guidelines. *Int J Surg*. déc 2018;60:132-6.
5. Bejarano PA. Gastrointestinal Stromal Tumors of the Stomach: A Clinicopathologic, Immunohistochemical, and Molecular Genetic Study of 1765 Cases With Long-term Follow-up. *Yearbook of Pathology and Laboratory Medicine*. Janv. 2007;2007:65-6.
6. Valsangkar N, Sehdev A, Misra S, Zimmers TA, O'Neil BH, Koniaris LG. Current management of gastrointestinal stromal tumors: Surgery, current biomarkers, mutations, and therapy. *Surgery*. Nov. 2015;158(5):1149-64.
7. Demetri GD, von Mehren M, Blanke CD, Van den Abbeele AD, Eisenberg B, Roberts PJ, et al. Efficacy and Safety of Imatinib Mesylate in Advanced Gastrointestinal Stromal Tumors. *N Engl J Med*. 15 août. 2002;347(7):472-80.
8. Sanchez-Hidalgo JM, Duran-Martinez M, Molero-Payan R, Rufian-Peña S, Arjona-Sanchez A, Casado-Adam A, et al. Gastrointestinal stromal tumors: A multidisciplinary challenge. *WJG*. 14 mai. 2018;24(18):1925-41.
9. Zhou L, Liao Y, Wu J, Yang J, Zhang H, Wang X, et al. Small bowel gastrointestinal stromal tumor: a retrospective study of 32

- cases at a single center and review of the literature. TCRM. Août. 2018;14:1467-81.
10. Ahmed M. Recent advances in the management of gastrointestinal stromal tumor. WJCC. 6 août. 2020;8 (15):3142-55.
  11. Ballati A, Essaidi Z, El Attar L, Errguibi D, Hajri A, Boufettal R, El Jai SR, Chehab F. A gastrointestinal stromal tumor of stomach presenting with an intratumoral abscess: A Case Report. Annals of Medicine and Surgery. 2021;63:102143.

---

© 2021 Hajri et al.; This is an Open Access article distributed under the terms of the Creative Commons Attribution License (<http://creativecommons.org/licenses/by/4.0>), which permits unrestricted use, distribution, and reproduction in any medium, provided the original work is properly cited.

*Peer-review history:*

*The peer review history for this paper can be accessed here:  
<http://www.sdiarticle4.com/review-history/69626>*