

Large Psoas Hematoma Complicating Anti-coagulant Therapy Poses a Diagnostic and Therapeutic Challenge

**Brahim Nassour A.^{1*}, Hissein Hagguir², Noel Mahoungou¹, Harouna Seydou¹,
Fadoul Adam¹, Salim Arous¹, Leila Azzouzi¹, Abdel Nasser Dirghil¹
and Rachida Habbal¹**

¹Cardiology Department, Ibn Rochd University Hospital, Casablanca, Morocco.

²Urology Department, Ibn Rochd University Hospital, Morocco.

Authors' contributions

This work was carried out in collaboration among all authors. All authors read and approved the final manuscript.

Article Information

DOI: 10.9734/CA/2021/v10i430177

Editor(s):

(1) Prof. Francesco Pelliccia, University La Sapienza, Italy.

Reviewers:

(1) Sameh Ibrahim, KFSH & RC, Saudi Arabia.

(2) Artur Dziewierz, Jagiellonian University, Poland.

Complete Peer review History: <https://www.sdiarticle4.com/review-history/75006>

Short Communication

Received 20 August 2021
Accepted 27 October 2021
Published 17 November 2021

ABSTRACT

Spontaneous psoas haematoma in patients on anti-coagulant therapy is a rare phenomenon. It poses a real diagnostic problem and a real therapeutic challenge. We report the case of a 51 year old patient, under anti-vitamin K (acenocoumarone) following a stenosing and tricuspid mitral plasty who presented with right lumbar pain radiating to the lower limb leading to functional impotence. Clinically, he was hemodynamically stable with a hematoma measuring 88x29 mm and extending to 161 mm. The ultrasound scan showed a large collection at the expense of the lumbar psoas muscle and the CT scan showed a swollen appearance of the right psoas muscle in its iliac portion. Management was conservative: discontinuation of anti-vitamin K, bed rest, antibiotic therapy, and monitoring (clinical, biological and radiological). The ultimate outcome was favourable.

Keywords: Heart disease; anti coagulant; anti vitamin K; haematoma; psoas.

*Corresponding author: E-mail: doctabra10aware@gmail.com;

1. INTRODUCTION

Spontaneous psoas haematoma in patients on anticoagulants is a rare phenomenon [1]. With a clinical symptomatology that is not very suggestive, it thus leads to a diagnostic problem. The CT scan plays an important role in the diagnosis [2,3]. The therapeutic attitude is not clearly established but is mainly dictated by the hemodynamic state of the patient. Based on a case encountered in our practice that posed a diagnostic and therapeutic challenge, we will discuss the various aspects of this entity with the data in the literature.

2. CLINICAL CASE

This is a 51 year old patient, on anti-vitamin K following a stenosed mitral and tricuspid plasty who presented with right lumbar pain radiating to the lower limb resulting in functional impotence. Clinically, the patient was conscious, hemodynamically and respiratorily stable with a heart rate of 86 beats per minute and a blood pressure of 120/80 mmHg. Ultrasound examination revealed a large collection in the right lumbar psoas measuring 67 mm in thickness. The complementary scan showed a swollen appearance of the right psoas muscle in its iliac portion, the site of a haematoma with hypodense, poorly limited areas measuring 88x29 mm and extending over 161 mm. There was associated thickening and infiltration of the

right iliac muscle. Biologically, the haemoglobin was 10 g/dl, white blood cells, platelets, PT and INR above 8. On echo cardiography we note a satisfactory operative result with pulmonary pressures that are not elevated and regular echo cardiographic monitoring was recommended.

3. DISCUSSION

The clinical manifestation of psoas haematoma is not specific [4,5]. Anatomically, the lumbar plexus in the psoas has two branches, the femoral-cutaneous nerve and the genitocrural nerve [6]. In case of significant compression of the femoral nerve by the haematoma, the main manifestation may be neurological. This could explain the symptomatology in our patient [7].

According to Wysowski et al, in about 4% of patients on anticoagulants, bleeding has been reported [8]. Psoas muscle haematomas are rare, accounting for 0.1-0.6%. The mortality rate is estimated at 30% [9]. Risk factors are age, anticoagulant therapy and haemodialysis [9]. Several imaging modalities (ultrasound, CT scan, MRI) are used to make the diagnosis [10,11]. However, CT is the most useful radiological method for diagnosis [12]. Ultrasound was able to provide information but CT was more accurate in characterising the collection and evoking the diagnosis of haematoma. In addition to characterising the collection, CT was able to provide information about the retroperitoneum.

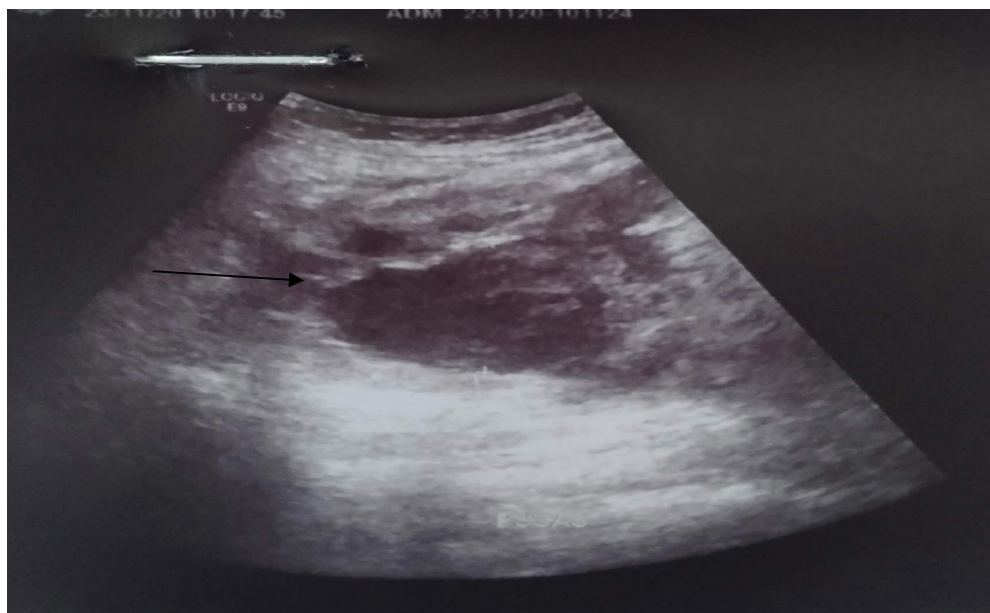


Image 1. Collection at the expense of the right lumbar psoas is 67 mm thick

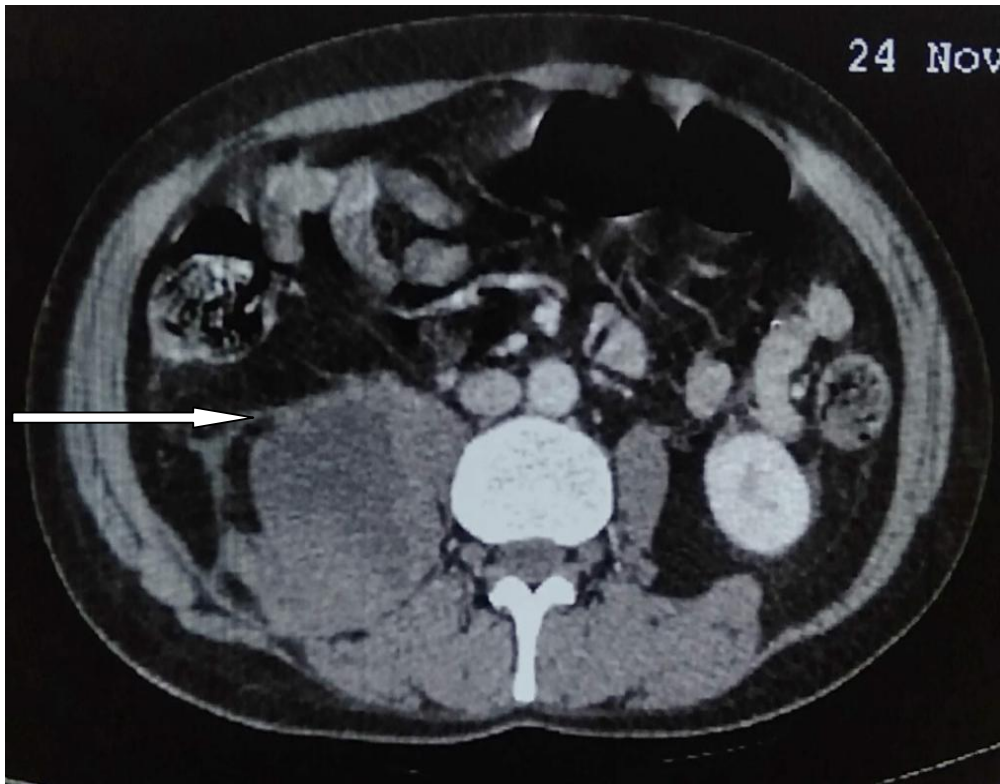


Image 2. Thickening and infiltration of the right iliac muscle

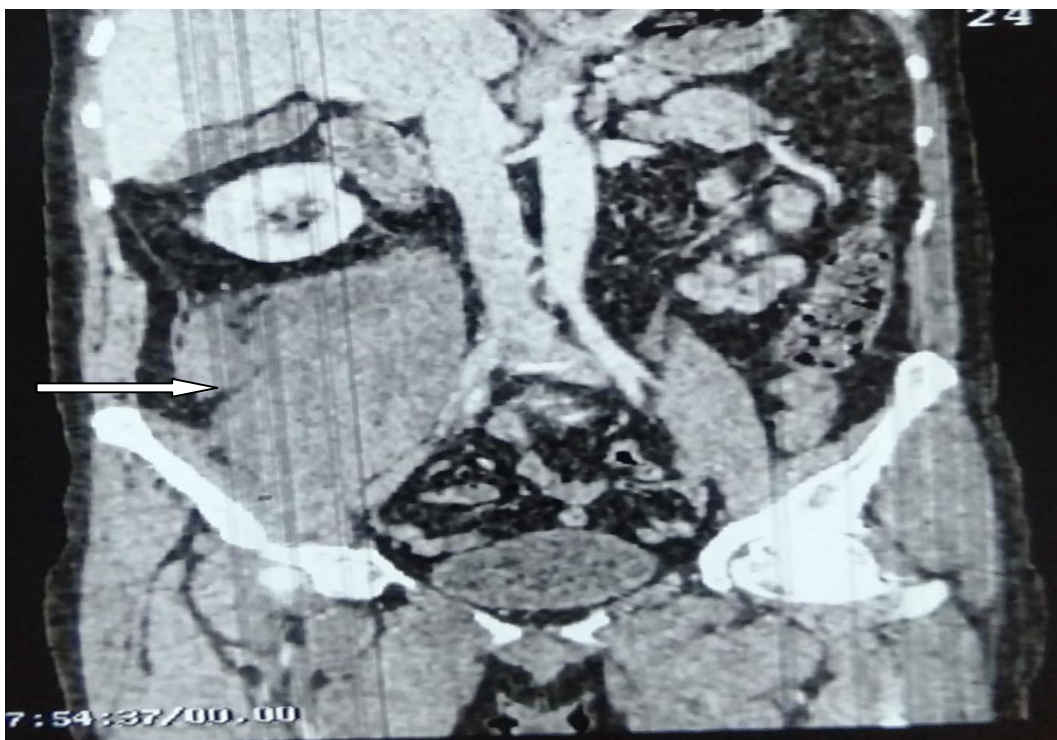

Image 3. Swollen appearance of the right psoas muscle in its iliac portion with hematoma

Depending on the haemodynamic status of the patient, treatment approaches include conservative treatment, surgical intervention or embolisation [13,14]. Although the conservative approach is the first choice, in case of haemodynamic instability and active bleeding, arterial catheter embolisation and surgical intervention may be necessary [15,16]. The treatment in our patient was conservative. The first course of action was to discontinue the anti vitamin K drug. In addition to the discontinuation of anticoagulant treatment, we recommended a strict diet, which strongly contributes to the imbalance of patients on anticoagulants. This conservative therapy consisted of bed rest, antibiotic therapy and clinical-biological and radiological monitoring. The ultimate evolution was favourable with progressive improvement of the symptomatology.

4. CONCLUSION

Patients on anticoagulant therapy are at high risk of bleeding and any new symptom should be considered for hidden bleeding. Conservative treatment in this situation is the best choice to avoid further complications.

CONSENT AND ETHICAL APPROVAL

As per university standard guideline, participant consent and ethical approval have been collected and preserved by the authors

COMPETING INTERESTS

Authors have declared that no competing interests exist.

REFERENCES

1. Shangxiang Liu, Chengqing Mei and coll : Iliopsoas hematoma associated with low-molecular-weight heparin use: A case report SAGE Open Medical Case Reports Volume 2020;8:1-4
2. Lefevre N, Bohu Y, Klouche S, et al. Complete paralysis of the quadriceps secondary to post-traumatic iliopsoas hematoma: a systematic review. Eur J Orthop Surg Traumatol 2015; 25(1):39-43.
3. Qian J, Jing JH, Tian DS, et al. Safety and efficacy of a new procedure for treating traumatic iliopsoas hematoma: a retroperitoneoscopic approach. Surg Endosc 2014; 28(1): 265-270.
4. Okumura T, Fujita H, Harada H, et al. A case report of idiopathic iliopsoas hematoma which occurred soon after transfer to the wheelchair after total hip arthroplasty. Nagoya J Med Sci 2017; 79(1): 65-73.
5. Podger H and Kent M. Femoral nerve palsy associated with bilateral spontaneous iliopsoas haematomas: a complication of venous thromboembolism therapy. Age Ageing 2016;45(1):175-176.
6. Zago G, Appel-da-Silva MC, Danzmann LC. Iliopsoas muscle hematoma during treatment with warfarin. Arq Bras Cardiol.2010
7. Llitjos JF, Daviaud F, Grimald D, Legriel S, Georges JL, Guerot E, Bedos JP, Fagon JY, Charpentier J, Mira JP. Ilio-psyas hematoma in the intensive care unit: a multicentric study. Ann Intensive Care. 2016;6(1):8.
8. Wysowski DK, Nourjah P, Swartz L. Bleeding complications with warfarin use: a prevalent adverse effect resulting in regulatory action. Arch Intern Med 2007; **167**:1414-9
9. Kurdoglu M, Onan MA, Turp A, et al. Spontaneous iliopsoas haematoma during heparin anticoagulation: cause of fetal loss. J Obstet Gynaecol 2008;28(5):543-544.
10. Butt MU, Buzsaki LA, Smyth SS, et al. Deep vein thrombosis complicated by spontaneous iliopsoas hematoma in patient with septic shock. Am J Case Rep 2017;18:1148-1152.
11. Choa GPH, Lim CS. Iliopsoas hematoma: an uncommon differential diagnosis for groin pain. Hong Kong J Emerg Med 2011; 18:173-176.
12. Lee KS, Jeong IS, Oh SG, et al. Subsequently occurring bilateral iliopsoas hematoma: a case report. J Cardiothor Surg 2015;10(1):183-186.
13. Daliakopoulos SI, Bairaktaris A, Papadimitriou D, et al. Gigantic retroperitoneal hematoma as a complication of anticoagulation therapy with heparin in therapeutic doses: a case report. J Med Case Rep 2008;2:162.
14. Casoni P, Dalla Valle R. Femoral neuropathy due to a spontaneous hematoma of the iliopsoas muscle during therapy with heparin-calcium. Acta Biomed Ateneo Parmense. 1994;65(5-6):289-96.
15. Marquardt G, Barduzal Angles S, Leheta F, Seifert V. Spontaneous haematoma of the iliac psoas muscle: a case report and

- review of the literature. Arch Orthop Trauma Surg. 2002;122(2):109-11.
16. Ozkan OF, Guner A, Cekic AB, Turan T, Kaya U, Reis, E. Iliopsoas haematoma: A rare complication of warfarin therapy. J Coll Physicians Surg Pak 2012;22(10):673-674.

© 2021 Brahim et al.; This is an Open Access article distributed under the terms of the Creative Commons Attribution License (<http://creativecommons.org/licenses/by/4.0>), which permits unrestricted use, distribution, and reproduction in any medium, provided the original work is properly cited.

Peer-review history:

The peer review history for this paper can be accessed here:
<https://www.sdiarticle4.com/review-history/75006>